

ISSN 2518-1629 (Online),  
ISSN 2224-5308 (Print)

ҚАЗАҚСТАН РЕСПУБЛИКАСЫ  
ҰЛТТЫҚ ҒЫЛЫМ АКАДЕМИЯСЫНЫҢ  
Өсімдіктердің биологиясы және биотехнологиясы институтының

# Х А Б А Р Л А Р Ы

---

---

## ИЗВЕСТИЯ

НАЦИОНАЛЬНОЙ АКАДЕМИИ НАУК  
РЕСПУБЛИКИ КАЗАХСТАН  
Института биологии и биотехнологии растений

## NEWS

OF THE NATIONAL ACADEMY OF SCIENCES  
OF THE REPUBLIC OF KAZAKHSTAN  
of the Institute of Plant Biology and Biotechnology

**БИОЛОГИЯ ЖӘНЕ МЕДИЦИНА  
СЕРИЯСЫ**



**СЕРИЯ**

**БИОЛОГИЧЕСКАЯ И МЕДИЦИНСКАЯ**



**SERIES**

**OF BIOLOGICAL AND MEDICAL**

**4 (328)**

**ШІЛДЕ – ТАМЫЗ 2018 ж.**

**ИЮЛЬ – АВГУСТ 2018 г.**

**JULY – AUGUST 2018**

1963 ЖЫЛДЫҢ ҚАҢТАР АЙЫНАН ШЫҒА БАСТАҒАН  
ИЗДАЕТСЯ С ЯНВАРЯ 1963 ГОДА  
PUBLISHED SINCE JANUARY 1963

ЖЫЛЫНА 6 РЕТ ШЫҒАДЫ  
ВЫХОДИТ 6 РАЗ В ГОД  
PUBLISHED 6 TIMES A YEAR

АЛМАТЫ, ҚР ҰҒА  
АЛМАТЫ, НАН РК  
ALMATY, NAS RK

Б а с р е д а к т о р

ҚР ҰҒА академигі, м. ғ. д., проф. **Ж. А. Арзықұлов**

**Абжанов Архат** проф. (Бостон, АҚШ),  
**Абелев С.К.**, проф. (Мәскеу, Ресей),  
**Айтқожина Н.А.**, проф., академик (Қазақстан)  
**Ақшулақов С.К.**, проф., академик (Қазақстан)  
**Алшынбаев М.К.**, проф., академик (Қазақстан)  
**Бәтпенев Н.Д.**, проф., корр.-мүшесі (Қазақстан)  
**Березин В.Э.**, проф., корр.-мүшесі (Қазақстан)  
**Берсімбаев Р.И.**, проф., академик (Қазақстан)  
**Беркінбаев С.Ф.**, проф., (Қазақстан)  
**Бисенбаев А.К.**, проф., академик (Қазақстан)  
**Бишимбаева Н.Қ.**, проф., академик (Қазақстан)  
**Ботабекова Т.К.**, проф., корр.-мүшесі (Қазақстан)  
**Жансүгірова Л.Б.**, б.ғ.к., проф. (Қазақстан)  
**Ellenbogen Adrian** prof. (Tel-Aviv, Israel),  
**Жамбакин Қ.Ж.**, проф., академик (Қазақстан), бас ред. орынбасары  
**Заядан Б.К.**, проф., корр.-мүшесі (Қазақстан)  
**Ishchenko Alexander** prof. (Villejuif, France)  
**Исаева Р.Б.**, проф., (Қазақстан)  
**Қайдарова Д.Р.**, проф., академик (Қазақстан)  
**Кохметова А.М.**, проф., корр.-мүшесі (Қазақстан)  
**Күзденбаева Р.С.**, проф., академик (Қазақстан)  
**Локшин В.Н.**, проф., корр.-мүшесі (Қазақстан)  
**Лось Д.А.**, prof. (Мәскеу, Ресей)  
**Lunenfeld Bruno** prof. (Израиль)  
**Макашев Е.К.**, проф., корр.-мүшесі (Қазақстан)  
**Миталипов Ш.М.** (Америка)  
**Муминов Т.А.**, проф., академик (Қазақстан)  
**Огарь Н.П.**, проф., корр.-мүшесі (Қазақстан)  
**Омаров Р.Т.**, б.ғ.к., проф., (Қазақстан)  
**Продеус А.П.** проф. (Ресей)  
**Purton Saul** prof. (London, UK)  
**Рахыпбеков Т.К.**, проф., корр.-мүшесі (Қазақстан)  
**Сапарбаев Мұрат** проф. (Париж, Франция)  
**Сарбасов Дос** проф. (Хьюстон, АҚШ)  
**Тұрысбеков Е.К.**, б.ғ.к., асс.проф. (Қазақстан)  
**Шарманов А.Т.**, проф. (АҚШ)

«ҚР ҰҒА Хабарлары. Биология және медициналық сериясы».

**ISSN 2518-1629 (Online),**

**ISSN 2224-5308 (Print)**

Меншіктенуші: «Қазақстан Республикасының Ұлттық ғылым академиясы» РҚБ (Алматы қ.)

Қазақстан республикасының Мәдениет пен ақпарат министрлігінің Ақпарат және мұрағат комитетінде  
01.06.2006 ж. берілген №5546-Ж мерзімдік басылым тіркеуіне қойылу туралы куәлік

Мерзімділігі: жылына 6 рет.

Тиражы: 300 дана.

Редакцияның мекенжайы: 050010, Алматы қ., Шевченко көш., 28, 219 бөл., 220, тел.: 272-13-19, 272-13-18,  
[www.nauka-nanrk.kz/biological-medical.kz](http://www.nauka-nanrk.kz/biological-medical.kz)

---

© Қазақстан Республикасының Ұлттық ғылым академиясы, 2018

Типографияның мекенжайы: «Аруна» ЖК, Алматы қ., Муратбаева көш., 75.

Г л а в н ы й р е д а к т о р

академик НАН РК, д.м.н., проф. **Ж. А. Арзыкулов**

**Абжанов Архат** проф. (Бостон, США),  
**Абелев С.К.** проф. (Москва, Россия),  
**Айтхожина Н.А.** проф., академик (Казахстан)  
**Акшулаков С.К.** проф., академик (Казахстан)  
**Алчинбаев М.К.** проф., академик (Казахстан)  
**Батпенов Н.Д.** проф. член-корр.НАН РК (Казахстан)  
**Березин В.Э.,** проф., чл.-корр. (Казахстан)  
**Берсимбаев Р.И.,** проф., академик (Казахстан)  
**Беркинбаев С.Ф.** проф. (Казахстан)  
**Бисенбаев А.К.** проф., академик (Казахстан)  
**Бишимбаева Н.К.** проф., академик (Казахстан)  
**Ботабекова Т.К.** проф., чл.-корр. (Казахстан)  
**Джансугурова Л. Б.** к.б.н., проф. (Казахстан)  
**Ellenbogen Adrian** prof. (Tel-Aviv, Israel),  
**Жамбакин К.Ж.** проф., академик (Казахстан), зам. гл. ред.  
**Заядан Б.К.** проф., чл.-корр. (Казахстан)  
**Ishchenko Alexander,** prof. (Villejuif, France)  
**Исаева Р.Б.** проф. (Казахстан)  
**Кайдарова Д.Р.** проф., академик (Казахстан)  
**Кохметова А.М.** проф., чл.-корр. (Казахстан)  
**Кузденбаева Р.С.** проф., академик (Казахстан)  
**Локшин В.Н.,** проф., чл.-корр. (Казахстан)  
**Лось Д.А.** prof. (Москва, Россия)  
**Lunenfeld Bruno** prof. (Израиль)  
**Макашев Е.К.** проф., чл.-корр. (Казахстан)  
**Миталипов Ш.М.** (Америка)  
**Муминов Т.А.** проф., академик (Казахстан)  
**Огарь Н.П.** проф., чл.-корр. (Казахстан)  
**Омаров Р.Т.** к.б.н., проф. (Казахстан)  
**Продеус А.П.** проф. (Россия)  
**Purton Saul** prof. (London, UK)  
**Рахыпбеков Т.К.** проф., чл.-корр. (Казахстан)  
**Сапарбаев Мурат** проф. (Париж, Франция)  
**Сарбасов Дос** проф. (Хьюстон, США)  
**Турьсыбеков Е. К.,** к.б.н., асс.проф. (Казахстан)  
**Шарманов А.Т.** проф. (США)

«Известия НАН РК. Серия биологическая и медицинская».

**ISSN 2518-1629 (Online),**

**ISSN 2224-5308 (Print)**

Собственник: РОО «Национальная академия наук Республики Казахстан» (г. Алматы)

Свидетельство о постановке на учет периодического печатного издания в Комитете информации и архивов  
Министерства культуры и информации Республики Казахстан №5546-Ж, выданное 01.06.2006 г.

Периодичность: 6 раз в год

Тираж: 300 экземпляров

Адрес редакции: 050010, г. Алматы, ул. Шевченко, 28, ком. 219, 220, тел. 272-13-19, 272-13-18,  
[www.nauka-nanrk.kz](http://www.nauka-nanrk.kz) / [biological-medical.kz](http://biological-medical.kz)

---

© Национальная академия наук Республики Казахстан, 2018

Адрес типографии: ИП «Аруна», г. Алматы, ул. Муратбаева, 75

## Editor in chief

**Zh.A. Arzykulov**, academician of NAS RK, Dr. med., prof.

**Abzhanov Arkhat**, prof. (Boston, USA),  
**Abelev S.K.**, prof. (Moscow, Russia),  
**Aitkhozhina N.A.**, prof., academician (Kazakhstan)  
**Akshulakov S.K.**, prof., academician (Kazakhstan)  
**Alchinbayev M.K.**, prof., academician (Kazakhstan)  
**Batpenov N.D.**, prof., corr. member (Kazakhstan)  
**Berezin V.Ye.**, prof., corr. member. (Kazakhstan)  
**Bersimbayev R.I.**, prof., academician (Kazakhstan)  
**Berkinbaev S.F.**, prof. (Kazakhstan)  
**Bisenbayev A.K.**, prof., academician (Kazakhstan)  
**Bishimbayeva N.K.**, prof., academician (Kazakhstan)  
**Botabekova T.K.**, prof., corr. member. (Kazakhstan)  
**Dzhansugurova L.B.**, Cand. biol., prof. (Kazakhstan)  
**Ellenbogen Adrian**, prof. (Tel-Aviv, Israel),  
**Zhambakin K.Zh.**, prof., academician (Kazakhstan), deputy editor-in-chief  
**Ishchenko Alexander**, prof. (Villejuif, France)  
**Isayeva R.B.**, prof. (Kazakhstan)  
**Kaydarova D.R.**, prof., academician (Kazakhstan)  
**Kokhmetova A.**, prof., corr. member (Kazakhstan)  
**Kuzdenbayeva R.S.**, prof., academician (Kazakhstan)  
**Lokshin V.N.**, prof., corr. member (Kazakhstan)  
**Los D.A.**, prof. (Moscow, Russia)  
**Lunenfeld Bruno**, prof. (Israel)  
**Makashev E.K.**, prof., corr. member (Kazakhstan)  
**Mitalipov Sh.M.** (America)  
**Muminov T.A.**, prof., academician (Kazakhstan)  
**Ogar N.P.**, prof., corr. member (Kazakhstan)  
**Omarov R.T.**, Cand. biol., prof. (Kazakhstan)  
**Prodeus A.P.**, prof. (Russia)  
**Purton Saul**, prof. (London, UK)  
**Rakhypbekov T.K.**, prof., corr. member. (Kazakhstan)  
**Saparbayev Murat**, prof. (Paris, France)  
**Sarbassov Dos**, prof. (Houston, USA)  
**Turysbekov E.K.**, cand. biol., assoc. prof. (Kazakhstan)  
**Sharmanov A.T.**, prof. (USA)

**News of the National Academy of Sciences of the Republic of Kazakhstan. Series of biology and medicine.**

**ISSN 2518-1629 (Online),**

**ISSN 2224-5308 (Print)**

Owner: RPA "National Academy of Sciences of the Republic of Kazakhstan" (Almaty)

The certificate of registration of a periodic printed publication in the Committee of information and archives of the Ministry of culture and information of the Republic of Kazakhstan N 5546-Ж, issued 01.06.2006

Periodicity: 6 times a year

Circulation: 300 copies

Editorial address: 28, Shevchenko str., of. 219, 220, Almaty, 050010, tel. 272-13-19, 272-13-18,  
<http://nauka-nanrk.kz/biological-medical.kz>

---

© National Academy of Sciences of the Republic of Kazakhstan, 2018

Address of printing house: ST "Aruna", 75, Muratbayev str, Almaty

## NEWS

OF THE NATIONAL ACADEMY OF SCIENCES OF THE REPUBLIC OF KAZAKHSTAN  
SERIES OF BIOLOGICAL AND MEDICAL

ISSN 2224-5308

Volume 4, Number 328 (2018), 5 – 19

UDC 616.13213-007.64

**R. M. Tuleutaev<sup>1</sup>, D. O. Urazbekov<sup>1</sup>, K. O. Ongarbayev<sup>1</sup>,  
K. B. Abzaliev<sup>1,2</sup>, B. A. Rakishev<sup>1</sup>, T. Yu. Ibragimov<sup>1</sup>,  
U. I. Imammyrzayev<sup>1</sup>, A. A. Oshakbaev<sup>1</sup>**

<sup>1</sup>"National Scientific Center of Surgery" named after A. N. Syzganova, Almaty, Kazakhstan,  
<sup>2</sup>Kazakh Medical Continuing Education University Joint Stock Company, Almaty, Kazakhstan.  
E-mail: rustemtuleutayev@gmail.com, dauren\_kgmu@mail.ru, yusuf\_28\_06\_1985@inbox.ru,  
abzaliev\_kuat@mail.ru, rakish@mail.ru, ibragimovteimur@mail.ru, ualikhan-88@mail.ru,  
lecherousslim@gmail.com

## **RECONSTRUCTIVE OPERATIONS IN AORTIC ROOF ANEURYSMS WITH AORTAL INSUFFICIENCY**

**Abstract.** Reconstructive surgery of the aortic root is of great interest in the field of cardiac surgery. Over the past three decades, a number of techniques, differing in technical performance and the anatomical area of the correction, have been proposed for the correction of aortic root aneurysm with aortic valve insufficiency. The purpose of these procedures is to maintain the functioning of the cusps and stabilize other components of the aortic root. Reliable and long-lasting effect of such interventions is particularly important due to the lack of necessity of taking anticoagulants. The choice of the method of surgical correction still remains controversial and in each case the surgeon is the one to make the decision. This review describes the methods of the aorta root reconstruction with a systematic approach of choosing a surgical correction method, accompanied by illustrations of the operations. The description of the procedures, followed by illustrations, facilitates the selection of the surgical method in each individual case.

**Keywords:** aortic root aneurysm, aortic insufficiency, reconstruction of aortic root.

**Introduction.** Most of the authors believed that the aortic aneurism is the local or widespread growth of its diameter for 1.5 times (Svensson L.G., 1997, Покровский А.В. 1979, Белов Ю.В. 2011). In most cases aortic root aneurism accompanies aortic valve's inefficiency. The most frequent mechanisms of aortic regurgitation with aortic aneurism are annule aortal ectasia, expansion of sinotubular junction and sinus of Valsalva's aneurism [84].

Over the past two decades, a number of methods were suggested for correction of aortic insufficiency, differing technical implementation and the anatomical area of aortic root. The purpose of these technics is saving functional leaflets by valve repair, replacement or stabilization of aortic root's other components [1]. Reliable and long-lasting effect of these interventions particularly beneficial, in the absence of the necessity of receiving anticoagulants.

The purpose of this article is to review development of operation methods, definition of indication to the use of different methods, based on the restoration of the functional anatomy of the complex – "aortic root".

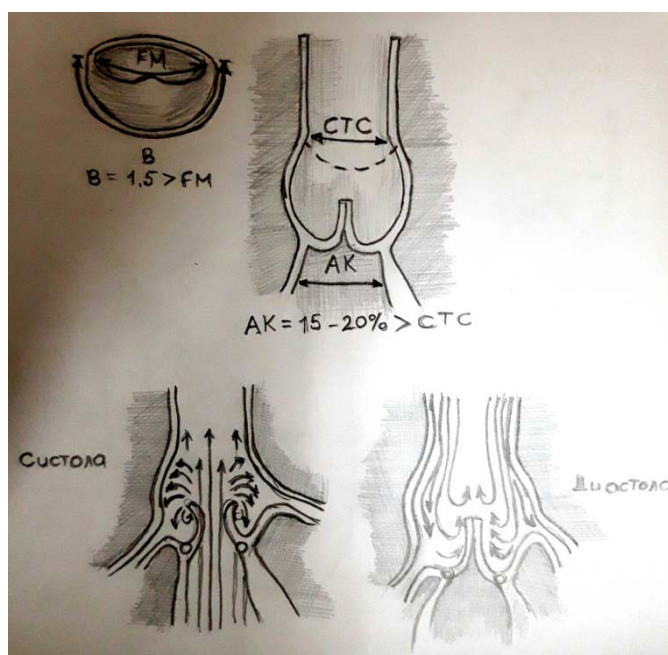
**Functional anatomy of the complex – "aortic root" and aortic valve.** In 1994, Kunzelman and co-authors published an important work describing the anatomy of aortic root and equilibration with aortic valve [2].

Finding of article was that the diameter of aortic root at the level of the middle Sinus was considered as 100%, and the diameter of that level of the sinus pecten made up 81% of diameter and size of normal aortic root bases left 97% of the first indicator

In other words, diameter of cinotubular ridge is approximately 85% of the aortic ring's diameter at the base of the root.

This quantified analysis of the aortic root's anatomy certifies da Vinci's theory about on Vortex flows created by cinotubular ridge (figure 1). Fluid's vortex flows arising between the edges of the folds of the valve leaflets and aortic wall create two effects:

1. In opening phase these flows avert contact valve leaflets with the wall of the aorta.
2. In closing phase flows initiate closing of leaflets



Cosing of aortic valve and flow division

$$AA = 15 - 20 \% > STJ$$

Figure 1 – Statistic and functional anatomy of aortic root. Sinotubular Junction's diameter (STJ) is less than aortic root's bottom (aortic rings – AA) for approximately 15%

The second effect described by authors, probably even more complicated than suggested, - the flow of the fluid causes the closing of valve on the systole's last moment and vortex flows protect leaflets from flexure and encourage their smooth and synchronized closure.

*Dynamic anatomy of the aortic root.* Dynamic Anatomy of the aortic root has been described for an understanding the mechanism of reducing stress on the leaf and thus avoiding aging and possible structural valve dysfunction [3-10]. A group of scientists from Stanford used radioactive marker on a model of sheep's aortic root, noting a number of complicated asymmetric deformations during the cardiac cycle, involving junctional zones (alleged aortic rings) and sinotubular junction as well as protraction, compression, expansion and aortic root stretching [3]. Lansac and co-authors' Four-dimensional study of aortic root confirm's that aortic root expansion begins at its base in isovolemic reduction phase and hence extends to the commissure valve and ultimately-sinotubular junction [4]. Maximum expansion of the aortic root get at the first third of systole, approaching the cylindrical form, then to mid-diastolic pressure goes reduction in volume, and the root became conoid. Aortic root enlargement for 39% and 63% in the commissural area, gives improvement of the blood outflow to systole, as well as makes the work of sinistral

stomach more effective. Lansac and Dagum's research explains the importance of interpetaloid triangles described in the works of Anderson and co-authors, which clearly define aortic ring as a valid subaortic structure consisting of 3 basic interpetaloid triangles, similar to the rack attachment line cusps of the aortic valve [3, 4, 9, 10]. Aortic root base tends to grow in accordance with kinetics ventricle.

Aortic root expands upward through disruption of 3 interpetaloid triangles, however, sinuses and sinotubular ridge maximum expands at the end of myocardia.

In addition, this aortic root's exact dynamic enlargement cycle, should be a specific chronology, also affecting to the position and degree of disjunction of the bottom on which attached leaflets of valves, as was first described Thubricar [10] (figure 1). All valve-preserving techniques, to varying degrees, change this dynamic geometry of the aortic root.

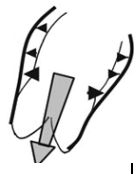
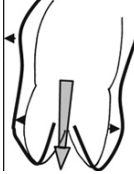
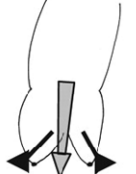


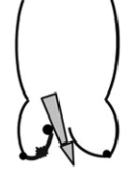
**Diseases at which valve-sparing surgery are possible.** Basically, all these reconstructive surgery are only applicable in cases where the aortic insufficiency is caused by the following lesions (table):

Aortic root enlargement repeated to the ascending aorta aneurism:

1. Mechanism of aortic insufficiency connected with the expansion of the sinotubular zone and disjunction commissure and incomplete Central koaptation leaflets of the aortic valve. Annulo-aortic ectasia and connective tissue disease as Marfan syndrome, Jellersa-Danlos syndrome and Lois-Dic: Sinus Valsalva's extension, sinotubular zones and the fibrous ring mechanism connected with cystic medial necrosis. Interesting that the valve leaflets are not affected.

2. The reason of aortic insufficiency in these syndromes connected with the progressive expansion of all components except the aortic root valve leaflets, which often leads to the dissection of the aortic wall. Acute or chronic aortic dissection: when aortic root aneurism dissections there is an aortic insufficiency or sinotubular valve extension (a), or detachment commissure with prolapse of leaflets (b). In the absence of damage to the leaflets, the aortic wall and pathology of aortic root, often possible the replacement and reconstruction of the aortic valve [11-27].

Reconstruction-oriented functional classification of aortic insufficiency  
(de Kerchove and El Khoury. Anatomy and pathophysiology of the VAJ DOI: 10.3978/j.issn.2225-319X.2012.12.05) (.)

Category	Type I — fibrous ring's dilation or cusp's fenestration in normal excursion				Type II Leaflets prolapse	Type III Limit of cusp's excursion
	Ia	Ib	Ic	Id		
Mechanism						
Repairing technique	Remodelling of CTC ascending aorta by prosthesis	valve-sparing surgery: reimplantation or remodeling with subcommutational annuloplasty	subcommutational annuloplasty	replacement with xenopericardial patch	– free fimbria's plication – free fimbria's resuspension – triangul exsection	– parietal exsection – decalcination – using of patch
Postprimary	subcommutational annuloplasty		annuloplasty of synotubular junction	subcommutational annuloplasty	subcommutational annuloplasty	subcommutational annuloplasty

In accordance with this approach, it is proposed:

1. In the case of ascending aorta, extending to CTC use replacement of ascending aorta and resuspension of CTC.

2. In the case of aneurism extending to sinus use remodeling procedure and subvalvular annuloplasty or reimplantation valve to prosthesis of ascending aorta

3. In the case of ring dilation implement different types of annuloplasty.

4. In the case of cusp perforation – reconstruction leaflets' autopericardium patch.

5. In the case of leaflets' prolapse:

a) reefing of free fimbria, it's resuspension, rehabilitate length prolapsing cusp by the use of pericardium;

b) sectoral exsection of excessive leaved tela.

6. In the case of leaflets' excursion limit:

a) use the method of triangular and parietal exsection shaving of free fimbria, fibrous incrassated fimbria for rehabilitate excursion , abolition commissural adherence;

b) rehabilitate length and integration shortened leaflets by use of autopericardium patch in order to assure leaflets' cooptation and regurgitation's liquidation

*Aortic valve conservation's efficiency.* The main idea of aortic valve conservation operations is the rehabilitation of functional anatomy of aortic root, because we often face the aortic root deformation without any structural and morphological changes on the part of valve leaflets [19, 20]. Aortic root reconstruction is more preferred than replacement , because there is no potential risk for complication as embolization of thrombus, prosthesis disfunction and endocarditis. The risk of early technical failures can be reduced through the regular usage intraoperative transoesophageal echocardiography and necessarily immediate interference until the moment of relocation to intensive cure unit.

#### **The history of development valve conservational surgery and plastic surgery to aortic root.**

Corrigan first described aortic insufficiency caused by the sinotubular junction's dilatation, without changes in valve leaflets. In 1913, Tuffier reported about the first aortic valve commissurotomy about his stenosis [23]. In 1956, Lewis published own plastic aortic valve technique and in 1985 Hapken reported about aortic stenosis's decalcification and plastic; at the first results of these plastic operations' were unsatisfactory, the effect was evanescent [22, 23].

In 1958, Taylor described the technique reducing the aortic insufficiency, which consisted circular saturation , coarctating and retracting the size of aortic ring and aortic aneurism [24]. In 1959 году, Starzl reported about the new technique of reducing aortic insufficiency through valve bicuspidization [25]. In 1960, Murphy described the technique of fibrous ring placcation in the case of syphilitic aotic root damage and aortic insufficiency, which implements without artificial blood circulation. It is similar to the Hurwit's technique. (1960). In 1958, Garamella published his aortic insufficiency therapy theory through commissure resuspension. This successful method became the important period in treatment development and understanding of core's semilunar valve fuctions [29].

In 1968, Bentall and De Bono, in a two-page message, described one patient who had replaced the aortic root and the ascending aorta with a composite prosthesis consisting of a suction tube and a valve prosthesis, the coronary artery mouth was implanted into the wall of the conduit. Subsequently, this technique became the gold standard in surgery of an aneurysm of the ascending aorta and bundle [30]. In 1980 and 1983, Wolfe reported on a series of reconstructive surgeries - aortic valve resuspension - performed in acute aortic dissection. In his work from 1983, 48 patients were reported, resuspension was successfully performed in 35 of them [29,30]. Only in one case, 17 years after the operation, the patient needed a reoperation - prosthetic repair of the aortic valve. In 1986, Frater described and emphasized the anatomical and mechanical function of the sinotubular junction, noting that correction of the extended sinotubular junction is often sufficient to eliminate aortic valve failure, provided that the valve flaps and its fibrous ring are not dilated [31].

**Development of modern methods of restoring the aortic valve in aneurysm and aortic dissection.** The technique was first described by M. De Bakey in 1956. It is one of the main valve-preserving surgeries for an aneurysm of the ascending aorta with associated aortic insufficiency caused by dilated STS [32, 33]. The technique consists in resection of the ascending aorta at the level of the STS, followed by the imposition of proximal anastomosis at the level of CTC with a synthetic aortic prosthesis (figure 2). Restoring the normal diameter of the CTC leads to the closeness of the valves and the restoration of coaptation, which eliminates aortic insufficiency. Back in 1986, Frater described and emphasized the anatomical and mechanical function of the sinotubular junction, indicating that only the reduction of the expanded sino-tubular junction can be performed to correct aortic insufficiency, provided that the valve flaps and its fibrous ring are not dilated. This technique is still widely used, showing good results in the long-term, especially in patients with aortic aneurysms without delamination.

The aortic valve resuspension technique is used today to correct all types of stratification, involving the ascending aorta above the synthubular crest or involving the non-coronary valve and its prolapse (figure 3).



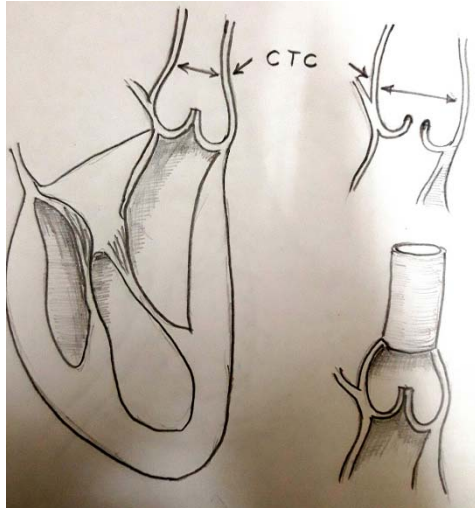


Figure 2 – Supracoronary prosthesis of the ascending aorta by Debaakey

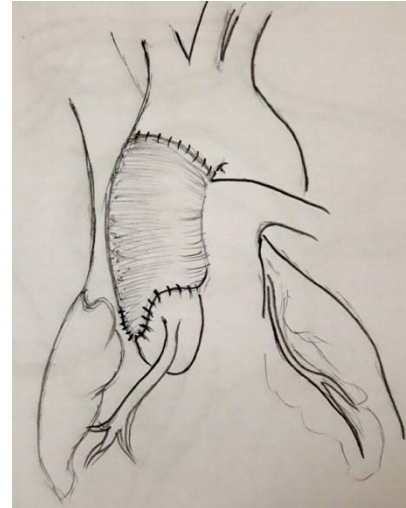


Figure 3 – Operation Wolfe

Surgery Wolfe, the non-coronary sinus (most often involved in the bundle) is excised and prosthethized by the tongue of the dacron prosthesis. The commissure posts of the valve are suspended in the Dacron tube, the biological glue is used to restore the exfoliated layers of the aorta, and also to seal the anastomoses of this reconstruction.

*Aortic valve reimplantation, David and Feindel technique: TD 1.* In 1992, David and Feindel reported a series of patients (n = 10) who underwent valve-conserving surgery for an aortic aneurysm with aortic insufficiency (34).

This technique is the purpose of this review and will be referred to as Tirone David 1 (TD1), consisting of a classic reimplantation of the aortic valve inside the dacronoptic prosthesis. To do this, aortic root resection was performed with the coronary arteries left on the sites and valve flaps on commissures with a 4-5 mm sinus wall site (figure 3, A, B). Dacron prosthesis was sutured to the base of the root of the aorta by stitches on the gaskets, the seams were placed below the valves of the AK so that they would pass through the fibrous skeleton of the base of the outlet part of the left ventricle (pseudo-ring). The valve commissures are sewn inside the Dacron tube in such a way, to achieve coaptation of the valves.

The operation is completed by sewing the coronary "pushes" to the neosinos and depositing the distal anastomosis (figure 4). Features of the reimplantation operation TD1 is a cylindrical reconstruction, reimplantation of the coronary arteries and maximum stabilization of the base of the root of the aorta (ring). In

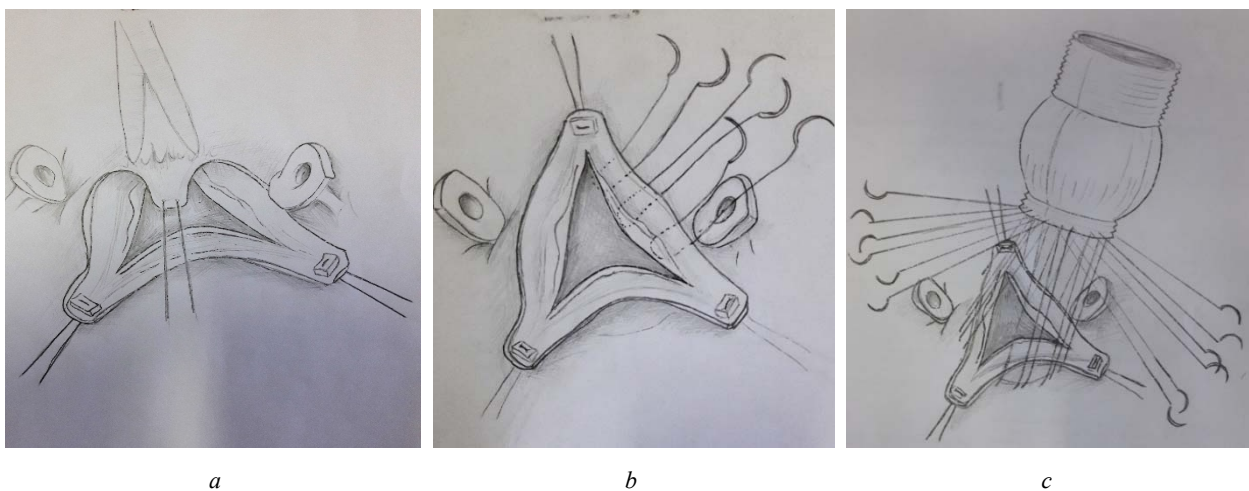


Figure 4 – Technique Tirone David 1, sequentially shows the stages of the operation, first described in 1992

the original technique, there is no description of the specificity of the sinotubular compound. Hvass reports a change in this technique in such a way that the dacron prosthesis is stitched inside the root of the aorta to the base of the valve flaps (in the David method – vice versa); Such a method of reimplantation has disadvantages – the AK leaflet contacts with the dacron tissue, and a stable fixation of the fibrous valve ring is not created [35].

Resection of the aneurysm of the ascending aorta, the valves and columns of the commissure of the valve are cut out, leaving the sinus wall at the edge of 3-5 mm, for suturing. The mouths of the coronary arteries are cut out on the "buttons". The vascular (dacron) prosthesis is sewn to the distal part of the ascending aorta. These sutures are sewn the end of the selected dacron prosthesis. The prosthesis was fixed to the base of the root of the aorta. The posts of the commissure are suspended inside the prosthesis with a continuous suturing seam, like the implantation technique of the subcoronary homograft. Anastomoses are applied with coronary arteries and a distal interstitial anastomosis.

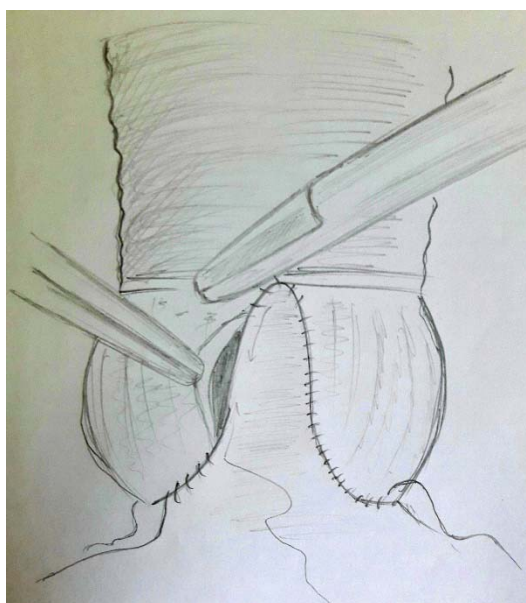


Figure 5 – The technique of remodeling the root of the aorta Yacoub, 1993

In 1993, Sarsam and Yacoub give a series of observations (10 patients) of surgical treatment of aortic insufficiency by a method called "remodeling of the aortic ring" [36].

The first version of the Yakub operation consisted of prosthetics of all three sinuses of Valsalva with reimplantation of the coronary arteries with the use of a dacron prosthesis truncated as a three-petal crown. The method involves reimplantation of the coronary arteries, but does not provide for the stabilization of the base of the aortic root and the determination of the size of the sinotubular junction (figure 5). In their technique, the authors emphasize the need to excise the sinuses of the aorta and the selection of a dacron tube of diameter equal to the diameter of the base of the root of the aorta. The incisions on the prosthesis are performed to increase the fixation height of the commissures of the valve. According to the name, a cylindrical reconstruction of the root of the aorta is performed, there is no specific narrowing at the site of the sinotubular junction, and there is no stabilization of the base of the aorta. Advantages of this method is technical simplicity, than with reimplantation, and allows more accurate resurrection of commissural racks. Subsequent modifications of the Yakub operation include a narrowing in the area of the sinotubular crest and the creation of swelling sinuses. Fig.5 Technique of remodeling Sarsam and Yacoub, 1993.

*Reimplantation or remodeling.* In 1995, David, Feindel and Boss reported the next step in the evolution of Tirone David's methodology. In the article "Reconstruction of the aortic valve with its insufficiency and aneurysm of the root of the aorta" [37], there are two fundamentally different recovery methods. The first was the reimplantation technique - TD1, which was used in patients with the expansion of sinotubular junctions, the destroyed or dilated sinus of Valsalva and with annuloaortal ectasia. An alter-

native technique, given immediately, was called "Tirone Davide-2" and described by the authors as a technique of "remodeling", was used in patients without annuloaortal ectasia, in most cases with Valsalva sinus deformity and the need for correction of the sinotubular junction. In this series, 45 patients were described, death was observed only in two cases. Nineteen patients were operated on by the reimplantation technique TD-1 and 26 by the TD-2 remodeling technique, the aortic valve was restored by reconstruction and prosthetics of all sinuses of the Valsalva coronary artery mouth was reimplanted into the prosthesis using the "push" technique. There was no strengthening or reduction of the "aortic ring", there was also no remodeling of the sinotubular junction (i.e., a decrease in diameter by 15% of the diameter of the outlet LV).

*Reimplantation of aortic root with reconstruction of pseudo-sinuses: Seattle technique methodology.* In 1995, Cochran and colleagues described a version of the operation of Tirone David, in which a Dacron tube with formed convex pseudo-sinuses was used, with the same valve retention technique [38]. In Seattle technique, the aortic valve is preserved and prosthetics of all sinuses of Valsalva is performed with reconstruction of neosinuses using special techniques. The swelling of these neo-sinus prevents the contact of the leaf with the dacron tissue. In the normal aorta, the valves are protected by dynamic geometry (dilatation of the sinuses, lengthening of the valves and root of the aorta). This technique also stabilizes the "aortic ring" with the proximal suture of the valve flaps below, similar to the TD-1 technique, as well as a distal seam, above the flaps, designed to maximize fixation of the commissure racks. Cutting out the petals at the proximal end of the prosthesis is necessary for the formation of neo-sinuses.

The hybrid technique was suggested by van Son and co-authors, in which the enlarged aortic root is reduced and reconstructed (coronary arteries are cut out on the buttons) by wedge-shaped excision of the Valsalva sinus walls, and then the reimplantation of the restored aortic root into the dacron tube, with careful restoration of the height of the commissural racks; The distal suture between the prosthesis and the root of the aorta is superimposed, and then the coronary arteries are filed [39]. This mixed technique allows the reconstruction of sinuses, taking into account the control of the diameters of the sinotubular junction and the fibrous ring, which avoids the contact of the valve with the dacron prosthesis, but does not stabilize the base of the root of the aorta. Some authors leave the "cushions" of the aortic wall, theoretically to protect the valves from damage [40, 41].

In 1996, T. David described another version of his remodeling method (TD-2), which is used for annuloaortal ectasia (TD-3 technique). In this case, the aortic valve is reconstructed by prosthetics of all those Valsalva sinuses, the coronary arteries are reimplanted into the prosthesis (figures 6, 7).

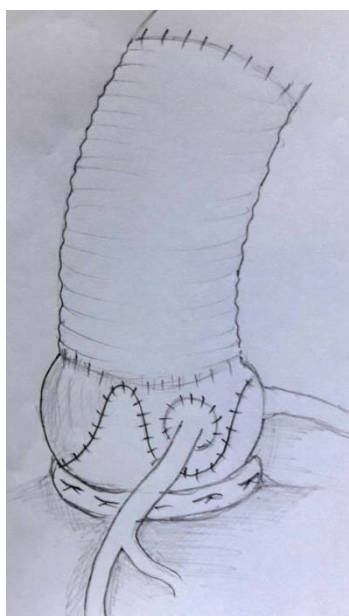


Figure 6 – Remodeling the root of the aorta with stabilization of the fibrous valve ring (TD-3)

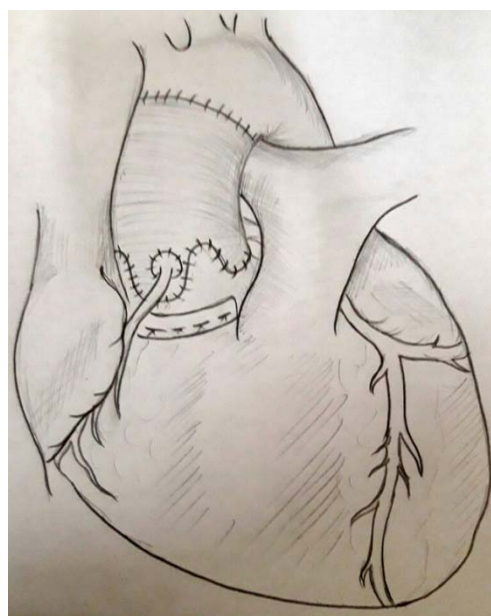


Figure 7 – Remodeling the root of the aorta with stabilization of the fibrous valve ring (TD-3)

The main difference of this technique is the strengthening of the root of the aorta and the fibrous ring with a teflon strip. This technique also provides an easier resuspension of the commissure columns, similar to the Yakub technique, and the remodeling of the sino-tubular junction does not depend on the size of the chosen prosthesis (figure 7 F-H). El Khoury and colleagues reported on this technique, but they limited themselves only to strengthening the aortic ring with significant dilatation; they also recommend the preservation of the intact sines of Valsalva [42].

Figures 6, 7. Remodeling Tirone David-3, 1996. Removal of the affected root of the aorta and the ascending aorta. The aorta intersects immediately above the sinotubular crest. The root of the aorta is mobilized to the very base, the coronary arteries are cut out on the sites. The aorta intersects immediately above the sinotubular crest. The root of the aorta is mobilized to the very base, the coronary arteries are cut out on the sites. The strip of Teflon is strengthened by the fibrosis of the exit region of the left ventricle, which gives stabilization of the base of the root of the aorta, especially necessary for annuloaortal ectasia. The diameter of the aortic ring (AA) was measured from it, the thickness of the aortic wall was subtracted, in order to determine the diameter of the necessary dacronoptic prosthesis. Aortic root remodeling method according to TD-3: Replacement of aortic root with a cut prosthesis. Adequate resuspension of the commissure. Reimplantation of coronary arteries into the corresponding sinuses.

*Recovery of the sinotubular crest.* This method consists of simple prosthetics of the ascending aorta with concomitant reconstruction (ie, constriction or reduction aortoplasty) of the sinotubular crest to restore normal co-aortic valves in the root of the aorta. As a separate method it can be used only with normal valves and sinuses of the Valsalva, and when the fibrous ring does not need reconstruction. Do not perform prosthetics of sinuses, and reimplantation of the coronary arteries. This operation does not carry in itself the strengthening and stabilization of the base of the root of the aorta, in essence this is the method of restoring the sinotubular junction, which Frater proposed [31]. Dr. David included this approach in his updated version of reimplantation (called Dr. Miller, as TD-4), in which he chooses a 4 mm dacron prosthesis larger than necessary and creates a sinotubular crest by its circular plication [43]. In the technique of reimplantation TD-5 or Miller-1, the dacron prosthesis is applied even 8 mm more than necessary, due to which synthetic pseudo-sinuses are formed [43, 44]. The "Jena" technique is hybrid, in which the reconstruction of the aortic root aneurysm is performed by plication and excision of a portion of the Valsalva sinus (U-shaped in the coronary and V-shaped in the non-coronary sinuses), and the sino-tubular junction is reduced by the dacron prosthesis (26-28 mm). The advantage of this method is the preservation of native tissue that contacts the valve flaps, as well as the dynamic properties of the root of the aorta, but there is a risk of further dilatation of the reconstruction zone [45].

**Remodeling of the root of the aorta with maximum stabilization, preservation of the valves and reconstruction of the sinotubular junction.** Hopkins proposed his method of reconstructing the aortic valve, but in essence, this is one of the varieties of remodeling. In this technique, all sinuses are replaced with reimplantation of the coronary arteries (similar to the Yacoub or TD-2 methods). The base of the root of the aorta is strengthened by a circular seam applied below the valves (figure 8), this protects the aortic

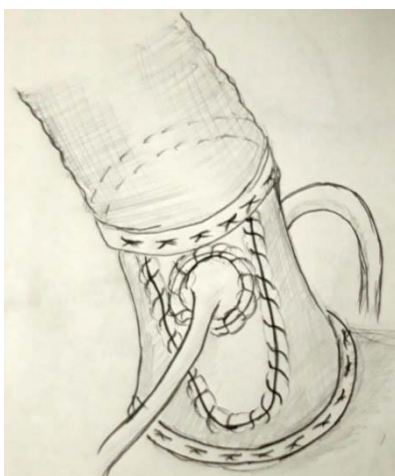

Figure 8



root enlargement in the following, and therefore is applicable to patients with congenital connective tissue defect, such as Marfan syndrome. As in Yacoub or TD-3 techniques, an uncomplicated procedure for resuspension of commissural racks is performed.

In this technique, the sinotubular junction is remodeled to ideal dimensions, i.e. 15% smaller than the diameter of the aortic ring, by selecting a dacron prosthesis smaller in diameter than the aortic ring, the sinuses slightly bulge outward, which is achieved by higher notches on the prosthesis, which are suspended by the commissure of the valve. The cuts on the prosthesis must be narrow to emphasize the place of the sinotubular transition, then the narrowing of this place is made by the Teflon strip. By narrowing the sinotubular junction, the functional flows described by Da Vinci that prevent the valves from contacting the dacronoptic prosthesis are retained. This reconstruction covers all components of the root of the aorta, while preserving the natural valves of the aortic valve.

Method of Hopkins-1. Narrowing strips of Teflon are applied circularly after excision of the pathologically altered aorta, and after the mobilization of its root. The proximal band is fixed by a series of mattress sutures, below the flaps. Commissures are kept with a site of surrounding tissue 3-5 mm. The notches in the proximal end of the prosthesis are made a bit longer, which will allow the commissure to be sutured even higher, and due to this, the neosinus will be convex. A proximal suture is applied at the base of the root of the aorta, the sinuses are replaced by the dacron prosthesis. Reimplantation of coronary mouths, the formation of constriction in the place where the commissure of the valve is sewn.

**Reimplantation of the root of the aorta into the prosthesis. Method of Florida Sleeve, described by R. Hess in 2005.** The ascending aorta crosses 1 cm above the sinotubular junction, the root of the aorta is allocated along the circumference to the level of the aortocastular contact. The diameter of the fibrous ring of the aortic valve is determined by using standard-sized meters. The distance from the base of the root of the aorta to the coronary arteries and the sinotubular crest for each commissure is also measured, which is necessary for the preparation of the prosthesis. The choice of prosthesis is performed at a rate of 4-5 mm larger than the measured diameter of the fibrous ring. The height of the skirt of the prosthesis should correspond to the measured height for each of the commissures, all commissures must be at the level of the sino-tubular crest of the prosthesis. Then, the coronary arteries are located on the prosthesis, after which vertical slots are made in the indicated positions in the form of a "keyhole". The length of the slits corresponds to the measured distance from the root of the aortic root to the lower part of the coronary artery. At the location of the coronary artery mouths, round holes are made. The next step is to place subannular U-shaped seams with a 3/0 woven with Teflon liners, placing them horizontally in a circle 1-2 mm below the aortic valve flaps from the inside out, so that the gaskets do not touch the cusps (figures 9, 10). In the area between the non-coronary and right coronary sinuses, seams must be placed along the contour of the valves to avoid complications from the side of the conductive system and the membrane part of the interventricular septum [46-48].

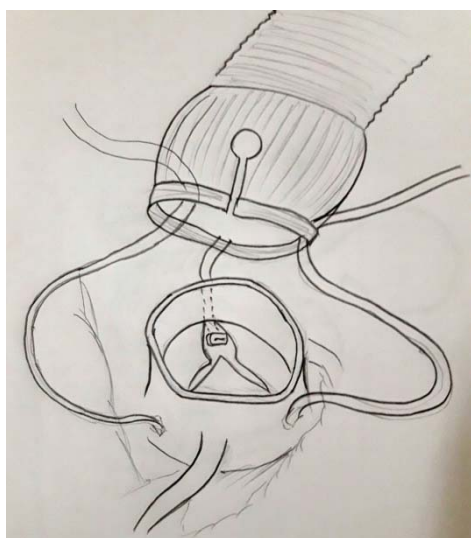


Figure 9 – Method of Florida Sleeve



Figure 10 – Method of Florida Sleeve

*Cases of failure of reimplantation and remodeling of the aortic valve.* Unsuccessful valve-preserving surgeries included procedures in which there is no adequate stabilization of the aortic base, and which in the long-term period lead to dilatation of the aortic ring [49]. Part of the output aortic tract forms a functional ring - in fact the bases of the interlobic triangles are below the fixation of the valves and is part of the ventricular hemodynamics [9, 10]. Proponents of reimplantation technology suggest that the stabilization of the aortic ring, especially in connective tissue diseases, is an important point. Remodeling methods leave these triangles intact, which should positively influence the surgery of the preserved flaps and the duration of reconstruction, since some elements of the dynamic expansion of the aortic root are preserved. Implantation methods support or fix these interlobular triangles.

The theoretical reason for the accelerated degeneration of the valves is systolic contact with the prosthetic wall, due to the lack of sinus expansion. Attempts to unsuccessfully reconstruct the root of the aorta with a ring size of 25-27 mm were attributed to the injury of the valves due to restraint in the prosthesis [11, 50-52]. Such complications can be during reimplantation in a cylindrical prosthesis or during remodeling, when a smaller prosthesis size is used. To avoid such problems, aortic prostheses with artificial sinuses of Valsalva are being developed [53].

Pethig and colleagues, using an echocardiographic study, determined that the level at which the leaflet coaptation occurs is an important factor in the long-term reconstruction. They divided all patients into three groups, depending on the level of coaptation: A – coaptation of the valves 2 mm above the plane of the aortic ring; B – at the level of the plane of the base of the ring; C – below the level of the base of the aortic ring. There was no regurgitation in group A (n = 56); in group B, severe AS occurred in 2 patients (n = 11); all patients from group C had AK deficiency (54).

Early methods of remodeling the root of the aorta (Yacoub, David-2) were aimed at prosthetics of pathologically altered sinuses of the Valsalva and preservation of the dynamic properties of the aorto-ventricular zone. However, in patients with connective tissue diseases, long-term complications associated with dilatation of unfortified aortic root components may develop, so this method developed further in the direction of greater stabilization of the base of the aorta and sinotubular zone.

Dr. David compared his reimplantation technique with developing remodeling methods in patients with an aortic root aneurysm and found some disparity in the long-term nature of these techniques. While the 8-10 year survival was excellent, his study showed the best results (ie freedom from developing moderate and severe AK insufficiency) for reimplantation technique [49]. He correctly noted that without strengthening, the root of the aorta can expand after many of the remodeling techniques. While, the technique of reimplantation theoretically has disadvantages - the contact of the cusps with synthetic "sinuses", in reality this is not a serious problem [49, 53, 55]. In addition, dacron prostheses with convex sinuses became available today [53, 56-58].

The extended service life of the reconstructed cusps can be achieved surgically by either Seattle technique or the use of prostheses proposed by Zehr [59] or the described David technique [49] or by using a Valsalva sinus prosthesis in combination with a smaller diameter tube, as in the Mayo Clinic [50]. However, the mechanism of the development of aortic insufficiency in the late period after the remodeling surgery is not entirely clear, most likely because of insufficient strengthening of the residual fibromuscular components of the complex - the root of the aorta, which is characteristic for this procedure.

In addition, problems can arise due to brittleness and postoperative degeneration and subsequent thinning of the cusps.

*Choosing the size of the prosthesis for reimplantation or remodeling.* A great attention was paid to the choice of the size of the prosthesis for various methods of reconstruction of the root of the aorta. The technique of reimplantation has the advantage of complete fixation of the whole complex of the root of the aorta and placement of the valve in the dacron prosthesis, however, its choice differs from the process of remodeling. Reimplantation requires the choice of a sufficiently large prosthesis, that would not increase the area of coaptation of the cusps. David stressed that the sinotubular junction can be formed either by narrowing the prosthesis or by sewing a smaller diameter prosthesis at the level of this junction if necessary; the procedure of reimplantation in general requires a fairly wide prosthesis (30-34 mm), which ideally corresponds to the size of the non-enlarged aortic ring. To select the size of the prosthesis in remodeling surgeries, several methods are described [3].

According to the method of M.Yacoub, in order to determine the required value commissures are stretched vertically, the position of the cusps is determined and their ability to coapt without prolapse; the necessary diameter is equal to the distance between the vertices of the commissure or one third of the aortic circle at the level of the sinotubular junction. David suggested first to normalize the aortic ring, and then choose a prosthesis, given that the diameter of the sinotubular transition is less than 15% of the aortic ring. This corresponds to the Kunzelman morphometry [2]. The Yakub group suggests that you also measure the distances between commissures, with the maximum coaptation of the wings, and then calculate the diameter of the prosthesis. K.Morishita et al. Have suggested to use the following formula:

$$d = 2 / \sqrt{3} \times id,$$

where  $d$  is the required diameter of the prosthesis,  $id$  is the distance between the commissure vertices.

David T. David's opinion is that the approximate diameter of the prosthesis is equal to the length of the free edge of the aortic valve leaf, minus 10% of the figure, but there is absolutely no exact formula for calculating the size of the prosthesis and the solution depends on the surgeon's experience. In valve-preserving surgeries with the reconstruction of the sinotubular ridge, the required diameter of the prosthesis is twice the height of the aortic valve leaflet. Dr. David noted that determining the size of the root of the aorta and the sinotubular junction is more an art than an exact science [60]. In his hands, the choice of prosthesis for reimplantation differs from that for remodeling [49]. The concept of choosing a prosthesis for reimplantation is based on the external diameter of the root of the aorta (internal diameter + wall thickness), while in remodeling - on the inner diameter. When remodeling, David is based on the size of the valves and does not recommend the use of prostheses less than 30 mm to avoid restriction of the sinuses and subsequent damage to the valves [49, 60, 66]. For remodeling, we described the following procedure. After excision of the sinuses, the true diameter of the aortoventricular connection is made with the help of the Gagar dilator. Horizontal horizontal mattresses are applied to the top of each commissural column, which are then stretched up to the appropriate diameter of the sinotubular junction, while a hydrodynamic coaptation test is performed. This diameter of the sinotubular zone usually corresponds to the internal diameter of the exit aortic tract, which was measured by Gagar. If the coaptation area of the semilunar valves seems insufficient, then a smaller diameter prosthesis should be selected. This is a very simple method (similar to David's artistic approach), where the narrowing of the prosthesis is combined with a strip of Teflon in the area of the sinotubular junction and an accurate selection of the commissure fixation height, which gives a reliable result of the reconstruction of the sinotubular junction zone without deformation of the sinuses.

The height of the commissure between the non-coronary-left coronary is measured to determine the size of the graft from the line connecting the nadir of two adjacent flaps (the base of the triangle between the rows) to the top of the commissure. This measurement corresponds to the size of the selected transplant; B. In the Gelweave Valsalva™ transplant (Vascutek Ltd, Terumo, Renfrewshire, Scotland), the height of the sinus part is equal to its diameter, which corresponds to the labeled size.

*Results of reconstruction of the root of the aorta with preservation or restoration of the aortic valve.* The level of surgery mortality varies from 0% to 6% [70,71] with a survival rate in 7 years 72-78% 8% [71, 72]. Patients with an aneurysm of the ascending aorta have a survival rate lower than those with an aortic root aneurysm, about 36% survive in the 8-year period [49]. This is a low survival rate, probably associated with the elderly age of patients with an aneurysm of VA, as well as concomitant vascular pathology. Resurgeries after aortic valve replacement for 7-8 years have a low frequency and according to many authors the freedom from this kind of rsurgeries is 90-97% [68, 71, 73]. Moderate aortic insufficiency is a rarity, especially during the first 2 years after surgery. However, the expressed AS is often close to 6%, although in some reports it reaches a level of up to 37% [34, 55, 73-78]. In addition to good survival rates in patients who underwent reconstruction of the root of the aorta, two-thirds of those observed are free from the risk of developing a moderate and severe degree of aortic valve failure within 8 years after surgery (49). David notes the superiority of reimplantation techniques (over remodeling) with a low risk of aortic insufficiency in the future; the average and severe AS was found in 10% for the 8-year period, while, when remodeling, this index was 45% [78]. The Hanover group achieved the same success in reimplantation of the aortic root, hospital mortality was 3.8%, and 4% were reoperated for aortic insufficiency [73]. Intraoperative transesophageal echocardiographic evaluation is important in determining

the long-term duration of the surgery [55]. Later complications (aortic insufficiency) in patients with connective tissue diseases are revealed more often, in methods where there is no maximum stabilization of the root of the aorta root ("ring") [60, 66-69,78-80].

Patients with an aneurysm of the root of the aorta and an intact root complex diseases, in which the reconstruction consisted of normalizing the diameter of the sinotubular zone, immediate and intermediate functional results are very good, and more than two-thirds of patients are free from development of the AS in the period of 8-10 years after surgery; however, the overall survival of these patients is relatively low, and only a third remains alive by the year 8, and possibly concomitant vascular disease and the age of the patients [49].

To compare the reconstruction technique, Dr. Gott and colleagues, examined the results of prosthetics in 235 patients with Marfan syndrome, 232 of whom underwent Bental's surgery and prosthetic aortic root replacement. In this group, there were no deaths in 30 days, 85% of these patients were alive at the time of publication of this article, and freedom from re-surgery for 20 years was 74% [81]. In the Japanese study, corrugated conduit was used, the operative mortality was 8.3%, and the actuary survival rate by the year 5 was 82.7% 4.8% [82].

Edwards and colleagues, using the National STS Cardiac Surgery database, determined the rates of operative mortality for isolated aortic valve replacement-4%; for patients with planned prosthetics AK-3,3% [83]. These data suggest that in selective patients, planned valve-saving surgeries are currently performed in most centers with a death rate approaching or better than for isolated aortic valve replacement.

**Conclusion.** The progress of these methods occurred after understanding the functional anatomy of the aortic root complex. Preliminary results of such surgeries support interest in their use, but an ideal and safe reconstruction technique, especially for connective tissue diseases, for example Marfan syndrome, should be determined after a longer period of postoperative follow-up (43). Today, there are many methods of reconstructing the root of the aorta, some of the original techniques have been replaced or modified by the same authors. The surgeon should consider the root of the aorta as a complex of elements, and strive to optimize its functional anatomy in each patient individually. The development of new types of prostheses also facilitates this task. Knowledge of the specific anatomy and history of the disease of each patient should help in the successful reconstruction of the aortic root complex with lasting effect and low lethality.

#### REFERENCES

- [1] Kouchoukos N.T., Wareing TH, Murphy SF, Perrillo JB. Sixteen-year experience with aortic root replacement. Results of 172 operations // *Ann Surg.* 1991; 214: 308-18; discussion.
- [2] Kunzelman KS, Grande J, David TE, Cochran RP, Verrier E. Aortic root and valve relationships: Impact on surgical repair // *J Thorac Cardiovasc Surg.* 1994; 107: 162-70.
- [3] Dagum P, Green GR, Mistal FJ, Daughters GT, Timek TA, Foppiano LE, Bolger AF, Ingels Jr MB, Miller DC. Deformation dynamics of the aortic root: modes and physiologic determinants // *Circulation.* 1999; 100 (Suppl. II): II-54-II-62.
- [4] Lansac E, Lim HS, Shomura Y, Lim KH, Rice NT, Goetz W, Acar C, Duran CMG. A four-dimensional study of the aortic root dynamics // *Eur J Cardiothoracic Surg.* 2002; 22: 497-503.
- [5] Thubrikar MJ, Nolan SP, Aouad J, Deck JD. Stress sharing between the sinus and leaflets of canine aortic valve // *Ann Thorac Surg.* 1986; 42: 434-40.
- [6] Brewer RJ, Deck JD, Capati B, Nolan SP. The dynamic aortic root. Its role in aortic valve function // *J Thorac Cardiovasc Surg.* 1976; 72: 413-7.
- [7] Thubrikar M, Harry R, Nolan SP. Normal aortic valve function in dogs // *Am J Cardiol* 1977; 40: 563-8.
- [8] Thubrikar M, Bosher LPNS. The mechanism of opening of the aortic valve // *J Thorac Cardiovasc Surg.* 1979; 77: 863-70.
- [9] Anderson RH, Devine WA, Ho SY, Smith A, McKay A. The myth of the aortic annulus: the anatomy of the subaortic outflow tract // *Ann Thorac Surg.* 1991; 52: 640-6.
- [10] Sutton JP, Ho SY, Anderson RH. The forgotten interleaflet triangles: a review of the surgical anatomy of the aortic valve // *Ann Thorac Surg.* 1995; 59: 419-27. Casselman FP, Tan ESH, Verneulen FEE, Kelder JC, Morshuis WJ, Schepens MAAM. Durability of aortic valve preservation and root reconstruction in acute Type A aortic dissection // *Ann Thorac Surg* 2000; 70: 1127-33.
- [11] Casselman FP, Tan ESH, Verneulen FEE, Kelder JC, Morshuis WJ, Schepens MAAM. Durability of aortic valve preservation and root reconstruction in acute Type A aortic dissection // *Ann Thorac Surg.* 2000; 70: 1127-33.
- [12] Graeter TP, Langer F, Nikoloudakis N, Aicher D, Schafers HJ. Valvepreserving operation in acute aortic dissection Type A // *Ann Thorac Surg.* 2000; 70: 1460-5.
- [13] Davies RR, Goldstein LJ, Coady MA, Tittle SL, Rizzo JA, Kopf GS, Elefteriades JA. Yearly rupture or dissection rates for thoracic aortic aneurysms: simple prediction based on size // *Ann Thorac Surg.* 2002; 73: 17-28.
- [14] Azakie A, David TE, Peniston CM, Rao V, Williams WG. Ruptured sinus of valsalva aneurysm: early recurrence and fate of the aortic valve // *Ann Thorac Surg.* 2000; 70: 1466-71.



- [15] Trusler GA, Moes CAF, Kidd BSL. Repair of ventricular septal defect with aortic insufficiency // *J Thorac Cardiovasc Surg.* 1973; 66: 394-403.
- [16] Vural KM, Sener E, Tasdemir O, Bayazit K. Approach to sinus of Valsalva aneurysms: a review of 53 cases // *Eur J Cardiothoracic Surg.* 2001; 20: 71-6.
- [17] Trusler GA, Williams WG, Smallhorn JF, Freedom RM. Late results after repair of aortic insufficiency associated with ventricular septal defect // *J Thorac Cardiovasc Surg.* 1992; 103: 276-81.
- [18] Rao V, van Arsdell GS, David TE, Azakie A, Williams WG. Aortic valve repair for adult congenital heart disease: a 22 year experience // *Circulation.* 2000; 1002 (Suppl. III): III-40-3.
- [19] Movsowitz HD, Levine RA, Hilgenberg AD, Isselbacher EM. Transesophageal echocardiographic description of the mechanisms of aortic regurgitation in acute Type A aortic dissection: implications for aortic valve repair // *J Am Coll Cardiol.* 2000; 36: 884-90.
- [20] Kamohara K, Itoh T, Natsuaki M, Norita H, Naito K. Early valve failure after aortic valve-sparing root reconstruction // *Ann Thorac Surg.* 1999; 68: 257-9.
- [21] Tuffier T. *État Actuel de la Chirurgie Intrathoracique* In *Surgery.* London: Congress Med. 1913: 247-327.
- [22] Lewis F, Shumway NE, Niazi SA, Benjamin RB. Aortic valvotomy under direct vision during hypothermia // *J Thoracic Surg.* 1956; 32: 481-99.
- [23] Harken D. The surgical treatment of acquired valvular disease // *Circulation.* 1958; 4: 128-30.
- [24] Taylor WJ, Thrower WB, Black H, Harken ED. The surgical correction of aortic insufficiency by circumelusion // *J Thoracic Surg.* 1958; 35: 192-205.
- [25] Starzl TC, Cruzat EP, Walker FB, Lewis JF. A technique for bicuspidization of the aortic valve // *J Thorac Cardiovasc Surg.* 1959; 38: 262-70.
- [26] Murphy JP. The surgical correction of syphilitic aortic insufficiency // *J Thorac Cardiovasc Surg.* 1960; 40: 524-8.
- [27] Garamella JJ. A new concept in surgical treatment of aortic insufficiency // *Minnesota Med.* 1958; 41: 260-2.
- [28] Bentall H, De Bono A. A technique for complete replacement of the ascending aorta // *Thorax.* 1968; 23: 338-9.
- [29] Wolfe WG, Oldham HN, Rankin JS, Moran JF. Surgical treatment of acute ascending aortic dissection // *Ann Surg.* 1983; 738-42.
- [30] Wolfe WG. Acute ascending aortic dissection // *Ann Surg.* 1980; 658-66.
- [31] Frater RW. Aortic valve insufficiency due to aortic dilatation: correction by sinus rim adjustment // *Circulation.* 1986; 74: 1136-42.
- [32] Boodhwani M, de Kerchove L, Glineur D, Rubay J, Vanoverschelde JL, Van Dyck M, Noirhomme P, El Khoury G. Aortic valve repair with ascending aortic aneurysms: associated lesions and adjunctive techniques // *Eur J Cardiothorac Surg.* Aug 2011. Vol. 40, 2. P. 424-428.
- [33] Cooley DA, De Bakey ME. Resection of entire ascending aorta in fusiform aneurysm using cardiac bypass // *J Am Med Assoc.* Nov 1956. Vol. 162, 12. P. 1158-1159.
- [34] David TE, Feindel CM. An aortic valve-sparing operation for patients with aortic incompetence and aneurysm of the ascending aorta // *J Thorac Cardiovasc Surg.* 1992; 103: 617-21.
- [35] Hvass U. A new technique for sparing the aortic valve in patients with aneurysm of the ascending aorta // *J Thorac Cardiovasc Surg.* 2000; 119: 1048-9.
- [36] Sarsam LAJ, Yacoub M. Remodeling of the aortic valve annulus // *J Thorac Cardiovasc Surg.* 1993; 105: 435-8.
- [37] David TE, Feindel CM, Bos J. Repair of the aortic valve in patients with aortic insufficiency and aortic root aneurysm // *J Thorac Cardiovasc Surg.* 1995; 109: 345-52.
- [38] Cochran RP, Kunzelman KS, Eddy AC, Hofer BO, Verrier ED. Modified conduit preparation creates a pseudosinus in an aortic valvesparing procedure for aneurysm of the ascending aorta // *J Thorac Cardiovasc Surg.* 1995; 109: 1049-58.
- [39] Van Son JAM, Battelini R, Mierzwa M, Walther T, Autschback R, Mohr FW. Aortic root reconstruction with preservation of native aortic valve and sinuses in aortic root dilatation with aortic regurgitation // *J Thorac Cardiovasc Surg.* 1999; 117: 1151-6.
- [40] Gelsomino S, Frassani R, Porreca L, Livi U. Aortic repair in Marfan's syndrome: prevention of mechanical leaflets damage // *Cardiovasc Surg.* 2001; 9: 299-301.
- [41] Svensson LG, Longoria J, Kimmel WA, Nadolny E. Management of aortic valve disease during aortic surgery // *Ann Thorac Surg.* 2000; 69: 778-84.
- [42] El Khoury GA, Underwood MJ, Glineur D, Derouck D, Dion RA. Reconstruction of the ascending aorta and aortic root: experience in 45 consecutive patients // *Ann Thorac Surg.* 2000; 70: 1246-50.
- [43] Miller DC. Valve-sparing aortic root replacement in patients with Marfan syndrome // *J Thorac Cardiovasc Surg.* 2003; 125: 773-8.
- [44] de Oliveira NC, David TE, Ivanov J, Armstrong S, Eriksson MJ, Rakowski H. Results of surgery for aortic root aneurysm in patients with Marfan syndrome // *J Thorac Cardiovasc Surg.* 2002; 125: 796-8.
- [45] Albes JM, Wahlers T. Valve-sparing root reduction plasty in aortic aneurysm: the 'Jena' technique // *Ann Thorac Surg.* 2003; 75: 1031-3.
- [46] Hess PJ Jr, Klodell CT, Beaver TM, Martin TD. The Florida sleeve: a new technique for aortic root remodeling with preservation of the aortic valve and sinuses // *Ann Thorac Surg.* 2005; 80: 748-50.
- [47] Hess PJ Jr, Harman PK, Klodell CT, et al. Early outcome using the Florida sleeve repair for correction of aortic insufficiency due to root aneurysms // *Ann Thorac Surg.* 2009; 87: 1161-8.
- [48] Chernjavskij A.M., Hvan D.S., Al'sov S.A., Sirota D.A., Ljashenko M.M. Rezul'taty reimplantacii kornija aorty v protez u pacientov s anevrizmoj voshodjashhego otdela aorty i nedostatochnost'ju aortal'nogo klapana // *Patologija krovoobrashhenija i kardiohirurgija.* 2015. Vol. 19, N 4. P. 38-47.

- [49] David TE, Ivanov J, Armstrong S, Feindel CM, Webb G. Aortic valve sparing operations in patients with aneurysms of the aortic root or ascending aorta // *Ann Thorac Surg.* 2002; 74: 1758-61.
- [50] Burkhart HM, Zehr KJ, Schaff HV, Daly RC, Dearani JA, Orszulak TA. Valve-preserving aortic root reconstruction: a comparison of techniques // *J Heart Valve Dis.* 2003; 12: 62-7.
- [51] Van Son JAM, Sim EKW, Starr A. Morphometric features of ruptured congenital sinus of Valsalva aneurysm implication for surgical treatment // *J Cardiovasc Surg.* 1995; 36: 433-6.
- [52] Gott VL, Gillinov AM, Pyeritz RE. Aortic root replacement: risk factor analysis of a seventeen-year experience with 270 patients // *J Thorac Cardiovasc Surg.* 1995; 109: 536-45.
- [53] De Paulis R, De Matteis GM, Nardi P, Scaffa R, Bassano C, Chiariello L. Analysis of valve motion after reimplantation type of valve-sparing procedure (David I) with a new aortic root conduit // *Ann Thorac Surg.* 2002; 74: 53-7.
- [54] Hopkins RA. Cardiac reconstructions with allograft tissues. New York, NY: Springer-Verlag, 2003.
- [55] Kallenbach K, Karck M, Leyh RG, Hagl C, Walles T, Harringer W, Havenrich A. Valve-sparing aortic root reconstruction in patients with significant aortic insufficiency // *Ann Thorac Surg.* 2002; 74: 1765-8.
- [56] Thubrikar MJ, Robicsek F, Gong GC, Fowler BL. A new aortic root prosthesis with compliant sinuses for valve-sparing operations // *Ann Thorac Surg.* 2001; 71: S318-22.
- [57] De Paulis R, De Matteis GM, Nardi P, Scaffa R, Colella DF, Bassano C, Tomai F, Chiariello L. One-year appraisal of a new aortic root conduit with sinuses of Valsalva // *J Thorac Cardiovasc Surg.* 2002; 123:33-9.
- [58] De Paulis R, De Matteis GM, Nardi P, Scaffa R, Buratta M, Chiariello L. Opening and closing characteristics of the aortic valve after valvesparing procedures using a new aortic root conduit // *Ann Thorac Surg.* 2001; 72: 487-94.
- [59] Zehr KJ, Thubrikar MJ, Gong GC, Headrick JR, Robicsek F. Clinical introduction of a novel prosthesis for valve-preserving aortic root reconstruction for annuloaortic ectasia // *J Thorac Cardiovasc Surg.* 2000; 120: 692-8.
- [60] David TE. Aortic valve sparing operations // *Ann Thorac Surg.* 2002; 73: 1029-30.
- [61] Morishita K, Murakami G, Koshino T, Fukada J, Fujisawa Y, Mawaaatari T, Abe T. Aortic root remodeling operation: how do we tailor a tube graft // *Ann Thorac Surg.* 2000; 73: 1117-21.
- [62] Pepper J, Yacoub M. Valve conserving operation for aortic regurgitation // *J Card Surg.* 1997; 12: 151-6.
- [63] Morishita K, Abe T, Fukada J, Sato H, Shiiku C. A surgical method for selecting appropriate size of graft in aortic root remodeling // *Ann Thorac Surg.* 1998; 65: 1795-6.
- [64] David TE. Aortic valve-sparing operations in patients with aortic root aneurysm. In: Piwnica A, Westaby S, editors. *Surgery for acquired valve disease.* Oxford: Isis medical Media; 1997. P. 135-43.
- [65] Choo SJ, Duran CMG. A surgical method for selecting appropriate size of graft in aortic root remodeling // *Ann Thorac Surg.* 1999; 67: 599-600.
- [66] David TE. Surgery of the aortic valve // *Curr Problems Surg.* 1999; 36: 426-504.
- [67] David TE. Remodeling of the aortic root and preservation of the native aortic valve // *OTCTS.* 1996; 1: 44-56.
- [68] Yacoub M, Gehle P, Chandrasekaran V, Birks EJ, Child A, Radley-Smith R. Late results of a valve-preserving operation in patients with aneurysm of the ascending aorta and root // *J Thorac Cardiovasc Surg.* 1998; 115: 1080-90.
- [69] Birks EJ, Webb C, Child A, Radley-Smith R, Yacoub M. Early and long-term results of a valve-sparing operation for Marfan syndrome // *Circulation.* 1999; 100 (Suppl II): 29-35.
- [70] David TE. Aortic valve-sparing operations for aortic root aneurysm // *Semin Thor Card Surg.* 2001; 13: 291-6.
- [71] David TE, Armstrong S, Ivanov J, Webb G. Aortic valve sparing operations: an update // *Ann Thorac Surg.* 2002; 67: 1840-2.
- [72] Izumoto H, Kawazoe K, Ishibashi K, Kim H, Kawase T, Nakajima T, Ohwawa S, Ishihara K, Satoh Y, Nasu M. Aortic valve repair in dominant aortic regurgitation // *J Thorac Cardiovasc Surg.* 2001; 49: 355-9.
- [73] Kallenbach K, Hagl C, Walles T, Leyh R, Pethig K, Haverich A, Harringer W. Results of valve-sparing aortic root reconstruction in 158 consecutive patients // *Ann Thorac Surg.* 2002; 74: 2026-33.
- [74] Westaby S, Katsumata T, Freitas E. Aortic valve conservation in acute type A dissection // *Ann Thorac Surg.* 1997; 64: 1108-12.
- [75] Pansini S, Gagliardotto PV, Ponpei E, Parisi F, Bardi G, Castenetto E, Orzan F, di Summa M. Early and late risk factors in surgical treatment of acute type A aortic dissection // *Ann Thorac Surg.* 1998; 66: 779-84.
- [76] Leyh RG, Schmidke C, Barlets C, Sievers HH. Valve-sparing aortic root replacement (remodeling/reimplantation) in acute type A dissection // *Ann Thorac Surg.* 2000; 70: 21-4.
- [77] Yacoub M, Fagan A, Stassano P, Radley-Smith R. Results of valve conserving operations for aortic regurgitation (abstract) // *Circulation.* 1983; 68: 311-2.
- [78] David TE, Armstrong S, Ivanov J, Feindel CM, Omran A, Webb G. Results of valve-sparing operations // *J Thorac Cardiovasc Surg.* 2001; 122: 39-46.
- [79] Luciani GB, Casali G, Tomezzoli A, Mazzucco A. Recurrence of aortic insufficiency after aortic root remodeling with valve preservation // *Ann Thorac Surg.* 1999; 67: 1849-52.
- [80] Schafers HJ, Fries R, Langer F, Nikoloudakis N, Graeter T, Grundmann U. Valve-preserving replacement of the ascending aorta: remodeling versus reimplantation // *J Thorac Cardiovasc Surg.* 1998; 116: 990-6.
- [81] Gott VL, Cameron DE, Alejo DE, Greene PS, Shake JG, Caparrelli DJ, Dietz HC. Aortic root replacement in 271 Marfan patients: a 24 year experience // *Ann Thorac Surg.* 2000; 73: 438-43.
- [82] Kirali K, Mansuroglu D, Omeroglu SN, Erentug V, Mataraci I, Ipek G, Alcinci E, Isik O, Yakut C. Five-Year Experience in aortic root replacement with the flanged composite graft // *Ann Thorac Surg.* 2002; 73: 1130-7.
- [83] Edwards FH, Peterson ED, Coombs LP, DeLong ER, Jamieson RE, Shroyer LW, Grover FL. Prediction of operative mortality after valve replacement surgery // *J Am Coll Cardiol.* 2001; 37: 885-92.
- [84] Tirone E. David. Surgical Treatment of Ascending Aorta and Aortic Root Aneurysms Progress in Cardiovascular Diseases. 52 (2010). 438-444. [www.onlinepcd.com](http://www.onlinepcd.com).

Р. М. Тулеутаев<sup>1</sup>, Д. О. Уразбеков<sup>1</sup>, К. О. Онгарбаев<sup>1</sup>, К. Б. Абзалив<sup>1,2</sup>,  
Б. А. Ракишев<sup>1</sup>, Т. Ю. Ибрагимов<sup>1</sup>, У. Е. Имаммырзаев<sup>1</sup>, А. А. Ошакбаев<sup>1</sup>

<sup>1</sup>АҚ «А. Н. Сызғанов атындағы Ұлттық ғылыми хирургия орталығы», Алматы, Қазақстан,

<sup>2</sup>«Қазақ медициналық үздіксіз білім беру университеті» акционерлік қоғамы, Алматы, Қазақстан

### ҚОЛҚА ҚАҚПАҚШАСЫНЫҢ ЖЕТІСПЕУШІЛІГІМЕН ҚОСАРЛАНҒАН ҚОЛҚА ТҮБІРІНІҢ АНЕВРИЗМАСЫ КЕЗІНДЕГІ РЕКОНСТРУКТИВТІ ОПЕРАЦИЯЛАР

**Аннотация.** Қазіргі таңда қолқа түбірінің аневризмасы кезіндегі реконструктивті операцияларға кардиохирургия саласында қызу талқылануда. Соңғы отыз жылдықта қолқа түбірінің аневризмасы кезінде жасалатын операциялардың бірнеше әдіс-тәсілдері ұсынылған. Олар бір-бірінен жасалу техникасы және түзету жүргізлетін анатомиялық аймағына байланысты ерекшеленеді. Бұл әдіс-тәсілдердің мақсаты қызметі сақталған жармаларды сақтап, қолқа түбірінің басқа бөліктерінің тұрақтандыру болып табылады. Бұл шаралардың беріктігі мен нәтижесінің ұзақ сақталуының маңыздылығы антикоагулянттарды қолдануда қажеттіліктің болмауында жатыр. Хирургиялық түзетудің әдіс-тәсілдерін таңдауда осы уақытқа дейін пікірталас бар, және әр жағдайда таңдау хирургқа қалады. Бұл шолуда қолқа түбірінің реконструктивті операцияларын таңдауды жүйелі түрде қаралған және операциялардың графикалық иллюстрациялармен берілген. Операциялардың иллюстрациялармен суреттелуі хирургтың әдіс-тәсілдерді таңдауын жеңілдетеді.

**Түйін сөздер:** аорта түбірінің аневризмасы, қолқа қақпақшасының жеткіліксіздігі, аорта түбірінің реконструкциясы.

Р. М. Тулеутаев<sup>1</sup>, Д. О. Уразбеков<sup>1</sup>, К. О. Онгарбаев<sup>1</sup>, К. Б. Абзалив<sup>1,2</sup>,  
Б. А. Ракишев<sup>1</sup>, Т. Ю. Ибрагимов<sup>1</sup>, У. Е. Имаммырзаев<sup>1</sup>, А. А. Ошакбаев<sup>1</sup>

<sup>1</sup>АО «Национальный Научный центр хирургии им. А. Н. Сызганова», Алматы, Казахстан,

<sup>2</sup>АО «Казахский медицинский университет непрерывного образования», Алматы, Казахстан

### РЕКОНСТРУКТИВНЫЕ ОПЕРАЦИИ ПРИ АНЕВРИЗМАХ КОРНЯ АОРТЫ С АОРТАЛЬНОЙ НЕДОСТАТОЧНОСТЬЮ

**Аннотация.** Реконструктивная хирургия корня аорты представляет большой интерес в области кардиохирургии. За последние три десятилетия был предложен ряд методик для коррекций аневризмы корня аорты с аортальной недостаточностью, различающиеся техническим выполнением и анатомической областью коррекции. Целью данных процедур является сохранение функционирующих створок и стабилизация других компонентов корня аорты. Надежный и длительный эффект таких вмешательств особенно важен ввиду отсутствия необходимости приема антикоагулянтов. Выбор метода хирургической коррекции до сих пор остается дискуссионным, и в каждом случае выбор остается за оперирующим хирургом. В данном обзоре описаны методы реконструкции корня аорты с систематическим подходом в выборе хирургического метода коррекции с графическими иллюстрациями операции. Описание операции с иллюстрациями способствуют упрощению выбора хирургического метода в каждом индивидуальном случае для хирурга.

**Ключевые слова:** аневризма корня аорты, аортальная недостаточность, реконструкция корня аорты.

#### About authors:

Tuleutaev Rustem Muhtarovich – head of cardiac surgery department at the National Scientific Center of Surgery A. N. Syzganov, candidate of Medicine, Almaty, Kazakhstan

Urazbekov Daurenbek Ongarbakovich – heart surgeon at the National Scientific Center of Surgery A. N. Syzganov, Almaty, Kazakhstan

Ongarbaev Kuanysh Ongarbaevich – heart surgeon at the National Scientific Center of Surgery A. N. Syzganov, Almaty, Kazakhstan

Abzaliev Kuat Bajandyevich – heart surgeon, high level certificate physician, candidate of Medicine, Kazakh Medical University of Continuing Education's cardiac surgery and roentgen-endovascular surgery subdepartment's head

Imammyrzaev Ualihan Esmahanovich – heart surgeon at the National Scientific Center of Surgery A. N. Syzganov, Almaty, Kazakhstan

Rakishev Bauyrzhan Aldabergenovich – heart surgeon at the National Scientific Center of Surgery A. N. Syzganov, Almaty, Kazakhstan

Oshakbaev Alibek Alhataevich – heart surgeon at the National Scientific Center of Surgery A. N. Syzganov, Almaty, Kazakhstan

Ibragimov Timur Juldashmirzaevich – heart surgeon at the National Scientific Center of Surgery A. N. Syzganov, Almaty, Kazakhstan

## **Publication Ethics and Publication Malpractice in the journals of the National Academy of Sciences of the Republic of Kazakhstan**

For information on Ethics in publishing and Ethical guidelines for journal publication see <http://www.elsevier.com/publishingethics> and <http://www.elsevier.com/journal-authors/ethics>.

Submission of an article to the National Academy of Sciences of the Republic of Kazakhstan implies that the described work has not been published previously (except in the form of an abstract or as part of a published lecture or academic thesis or as an electronic preprint, see <http://www.elsevier.com/postingpolicy>), that it is not under consideration for publication elsewhere, that its publication is approved by all authors and tacitly or explicitly by the responsible authorities where the work was carried out, and that, if accepted, it will not be published elsewhere in the same form, in English or in any other language, including electronically without the written consent of the copyright-holder. In particular, translations into English of papers already published in another language are not accepted.

No other forms of scientific misconduct are allowed, such as plagiarism, falsification, fraudulent data, incorrect interpretation of other works, incorrect citations, etc. The National Academy of Sciences of the Republic of Kazakhstan follows the Code of Conduct of the Committee on Publication Ethics (COPE), and follows the COPE Flowcharts for Resolving Cases of Suspected Misconduct ([http://publicationethics.org/files/u2/New\\_Code.pdf](http://publicationethics.org/files/u2/New_Code.pdf)). To verify originality, your article may be checked by the Cross Check originality detection service <http://www.elsevier.com/editors/plagdetect>.

The authors are obliged to participate in peer review process and be ready to provide corrections, clarifications, retractions and apologies when needed. All authors of a paper should have significantly contributed to the research.

The reviewers should provide objective judgments and should point out relevant published works which are not yet cited. Reviewed articles should be treated confidentially. The reviewers will be chosen in such a way that there is no conflict of interests with respect to the research, the authors and/or the research funders.

The editors have complete responsibility and authority to reject or accept a paper, and they will only accept a paper when reasonably certain. They will preserve anonymity of reviewers and promote publication of corrections, clarifications, retractions and apologies when needed. The acceptance of a paper automatically implies the copyright transfer to the National Academy of Sciences of the Republic of Kazakhstan.

The Editorial Board of the National Academy of Sciences of the Republic of Kazakhstan will monitor and safeguard publishing ethics.

Правила оформления статьи для публикации в журнале смотреть на сайте:

[www.nauka-nanrk.kz](http://www.nauka-nanrk.kz)

**ISSN 2518-1629 (Online), ISSN 2224-5308 (Print)**

<http://www.biological-medical.kz/index.php/ru/>

Редактор *М. С. Ахметова, Т. М. Апендиев, Д. С. Аленов*  
Верстка на компьютере *Д. Н. Калкабековой*

Подписано в печать 11.07.2018.

Формат 60x881/8. Бумага офсетная. Печать – ризограф.  
9,2 п.л. Тираж 300. Заказ 4.