

ISSN 2518-1629 (Online),
ISSN 2224-5308 (Print)

ҚАЗАҚСТАН РЕСПУБЛИКАСЫ
ҰЛТТЫҚ ҒЫЛЫМ АКАДЕМИЯСЫНЫҢ
Өсімдіктердің биологиясы және биотехнологиясы институтының

Х А Б А Р Л А Р Ы

ИЗВЕСТИЯ

НАЦИОНАЛЬНОЙ АКАДЕМИИ НАУК
РЕСПУБЛИКИ КАЗАХСТАН
Института биологии и биотехнологии растений

NEWS

OF THE NATIONAL ACADEMY OF SCIENCES
OF THE REPUBLIC OF KAZAKHSTAN
of the Institute of Plant Biology and Biotechnology

**БИОЛОГИЯ ЖӘНЕ МЕДИЦИНА
СЕРИЯСЫ**



СЕРИЯ

БИОЛОГИЧЕСКАЯ И МЕДИЦИНСКАЯ



SERIES

OF BIOLOGICAL AND MEDICAL

5 (317)

**ҚЫРКҮЙЕК – ҚАЗАН 2016 ж.
СЕНТЯБРЬ – ОКТЯБРЬ 2016 г.
SEPTEMBER – OCTOBER 2016**

1963 ЖЫЛДЫҢ ҚАҢТАР АЙЫНАН ШЫҒА БАСТАҒАН
ИЗДАЕТСЯ С ЯНВАРЯ 1963 ГОДА
PUBLISHED SINCE JANUARY 1963

ЖЫЛЫНА 6 РЕТ ШЫҒАДЫ
ВЫХОДИТ 6 РАЗ В ГОД
PUBLISHED 6 TIMES A YEAR

АЛМАТЫ, ҚР ҰҒА
АЛМАТЫ, НАН РК
ALMATY, NAS RK

Б а с р е д а к т о р

ҚР ҰҒА академигі, м. ғ. д., проф.

Ж. А. Арзықұлов

Абжанов Архат проф. (Бостон, АҚШ),
Абелев С.К. проф. (Мәскеу, Ресей),
Айтқожина Н.А. проф., академик (Қазақстан)
Акшулаков С.К. проф., корр.-мүшесі (Қазақстан)
Алшынбаев М.К. проф., корр.-мүшесі (Қазақстан)
Березин В.Э., проф., корр.-мүшесі (Қазақстан)
Бисенбаев А.К. проф., корр.-мүшесі (Қазақстан)
Бишимбаева Н.К. проф., корр.-мүшесі (Қазақстан)
Ботабекова Т.К. проф., корр.-мүшесі (Қазақстан)
Bosch Ernesto prof. (Spain)
Ellenbogen Adrian prof. (Tel-Aviv, Israel),
Жамбакин К.Ж. проф., корр.-мүшесі (Қазақстан), бас ред. орынбасары
Ishchenko Alexander, prof. (Villejuif, France)
Қайдарова Д.Р. проф., корр.-мүшесі (Қазақстан)
Күзденбаева Р.С. проф., академик (Қазақстан)
Лось Д.А. prof. (Мәскеу, Ресей)
Lunefeld Bruno prof. (Израиль)
Миербеков Е.М. проф. (Қазақстан)
Муминов Т.А. проф., академик (Қазақстан)
Purton Saul prof. (London, UK)
Рахыпбеков Т.К. проф., корр.-мүшесі (Қазақстан)
Сапарбаев Мұрат проф. (Париж, Франция)
Сарбассов Дос проф. (Хьюстон, АҚШ)

«ҚР ҰҒА Хабарлары. Биология және медициналық сериясы».

ISSN 2518-1629 (Online),

ISSN 2224-5308 (Print)

Меншіктенуші: «Қазақстан Республикасының Ұлттық ғылым академиясы» РҚБ (Алматы қ.)

Қазақстан республикасының Мәдениет пен ақпарат министрлігінің Ақпарат және мұрағат комитетінде
01.06.2006 ж. берілген №5546-Ж мерзімдік басылым тіркеуіне қойылу туралы куәлік

Мерзімділігі: жылына 6 рет.

Тиражы: 300 дана.

Редакцияның мекенжайы: 050010, Алматы қ., Шевченко көш., 28, 219 бөл., 220, тел.: 272-13-19, 272-13-18,
www.nauka-nanrk.kz / biological-medical.kz

© Қазақстан Республикасының Ұлттық ғылым академиясы, 2016

Типографияның мекенжайы: «Аруна» ЖК, Алматы қ., Муратбаева көш., 75.

Г л а в н ы й р е д а к т о р
академик НАН РК, д.м.н., проф.

Ж. А. Арзыкулов

Абжанов Архат проф. (Бостон, США),
Абелев С.К. проф. (Москва, Россия),
Айтхожина Н.А. проф., академик (Казахстан)
Акшулаков С.К. проф., чл.-корр. (Казахстан)
Алчинбаев М.К. проф., чл.-корр. (Казахстан)
Березин В.Э., проф., чл.-корр. (Казахстан)
Бисенбаев А.К. проф., чл.-корр. (Казахстан)
Бишимбаева Н.К. проф., чл.-корр. (Казахстан)
Ботабекова Т.К. проф., чл.-корр. (Казахстан)
Bosch Ernesto prof. (Spain)
Ellenbogen Adrian prof. (Tel-Aviv, Israel),
Жамбакин К.Ж. проф., чл.-корр. (Казахстан), зам. гл. ред.
Ishchenko Alexander prof. (Villejuif, France)
Кайдарова Д.Р. проф., чл.-корр. (Казахстан)
Кузденбаева Р.С. проф., академик (Казахстан)
Лось Д.А. prof. (Москва, Россия)
Lunenfeld Bruno prof. (Израиль)
Миербеков Е.М. проф. (Казахстан)
Муминов Т.А. проф., академик (Казахстан)
Purton Saul prof. (London, UK)
Рахыпбеков Т.К. проф., чл.-корр. (Казахстан)
Сапарбаев Мурат проф. (Париж, Франция)
Сарбассов Дос проф. (Хьюстон, США)

«Известия НАН РК. Серия биологическая и медицинская».

ISSN 2518-1629 (Online),

ISSN 2224-5308 (Print)

Собственник: РОО «Национальная академия наук Республики Казахстан» (г. Алматы)

Свидетельство о постановке на учет периодического печатного издания в Комитете информации и архивов
Министерства культуры и информации Республики Казахстан №5546-Ж, выданное 01.06.2006 г.

Периодичность: 6 раз в год

Тираж: 300 экземпляров

Адрес редакции: 050010, г. Алматы, ул. Шевченко, 28, ком. 219, 220, тел. 272-13-19, 272-13-18,

www.nauka-nanrk.kz/biological-medical.kz

© Национальная академия наук Республики Казахстан, 2016

Адрес типографии: ИП «Аруна», г. Алматы, ул. Муратбаева, 75

Editor in chief

academician of NAS RK, doctor of medical science, professor

Zh. A. Arzykulov

Abzhanov Arkhat prof. (Boston, USA),
Abelev S.K. prof. (Moscow, Russia),
Aitkhozhina N.A. prof., academician (Kazakhstan)
Akshulakov S.K. prof., corr. member. (Kazakhstan)
Alchinbayev M.K. prof., corr. member. (Kazakhstan)
Berezin V.Ye., prof., corr. member. (Kazakhstan)
Bisenbayev A.K. prof., corr. member. (Kazakhstan)
Bishimbayeva N.K. prof., corr. member. (Kazakhstan)
Botabekova T.K. prof., corr. member. (Kazakhstan)
Bosch Ernesto prof. (Spain)
Ellenbogen Adrian prof. (Tel-Aviv, Israel),
Zhambakin K.Zh. prof., corr. member. (Kazakhstan), deputy editor in chief
Ishchenko Alexander, prof. (Villejuif, France)
Kaydarova D.R. prof., corr. member. (Kazakhstan)
Kuzdenbayeva R.S. prof., academician (Kazakhstan)
Los D.A. prof. (Moscow, Russia)
Lunenfeld Bruno prof. (Israel)
Miyerbekov Ye.M. prof. (Kazakhstan)
Muminov T.A. prof., academician (Kazakhstan)
Purton Saul prof. (London, UK)
Rakhypbekov T.K. prof., corr. member. (Kazakhstan)
Saparbayev Murat prof. (Paris, France)
Sarbassov Dos, prof. (Houston, USA)

News of the National Academy of Sciences of the Republic of Kazakhstan. Series of biology and medicine.

ISSN 2518-1629 (Online),

ISSN 2224-5308 (Print)

Owner: RPA "National Academy of Sciences of the Republic of Kazakhstan" (Almaty)

The certificate of registration of a periodic printed publication in the Committee of information and archives of the Ministry of culture and information of the Republic of Kazakhstan N 5546-Ж, issued 01.06.2006

Periodicity: 6 times a year

Circulation: 300 copies

Editorial address: 28, Shevchenko str., of. 219, 220, Almaty, 050010, tel. 272-13-19, 272-13-18,
<http://nauka-nanrk.kz> / biological-medical.kz

© National Academy of Sciences of the Republic of Kazakhstan, 2016

Address of printing house: ST "Aruna", 75, Muratbayev str, Almaty

NEWS

OF THE NATIONAL ACADEMY OF SCIENCES OF THE REPUBLIC OF KAZAKHSTAN

SERIES OF BIOLOGICAL AND MEDICAL

ISSN 2224-5308

Volume 5, Number 317 (2016), 5 – 10

UDC [616.12-089+616.13-089]:616.132.2

**I. Ye. Sagatov^{1,2}, Jun Tae-Gook³, Song Jinyoung³,
K. O. Ongarbayev¹, U. Ye. Imammyrzaev¹, A. B. Aimambetova¹**

¹A. N. Syzganov National Scientific Center of Surgery,

²Kazakh Medical University of Continuous Education, Almaty, Kazakhstan,

³Samsung Medical Center School of Medicine, Sungyunkwan University, Seoul, South Korea

CLINICAL CASE OF THE SURGICAL TREATMENT OF A 6-YEAR-OLD CHILD WITH ALCAPA (BLAND-WHITE-GARLAND SYNDROME)

Abstract. This article presents a case report of successful surgical treatment of 6 years old patient with ALCAPA (Bland-White-Garland syndrome).

Key words: ALCAPA, children.

Introduction. The first mention of Anomalous Left Coronary Artery from the Pulmonary Artery or ALCAPA belongs to S. J. Brooks [5]. Subsequently in 1908 M. Abbott has described similar pathology in 60-year-old woman who has died suddenly [2]. The first clinical description belongs to a group of authors – E. F. Bland, P. White and J. Garland (1933), therefore this anomaly is also known as a Bland-White-Garland syndrome [3]. Nowadays the prognosis of this disease is rather favorable in connection with a possibility of early diagnostics by means of an echocardiography, and also improvement of a technique and results of surgical treatment [1, 4-12].

Frequency of ALCAPA makes about 0,25–0,46% of all congenital heart diseases [4-8, 11, 12]. According to data of various authors, it is found at 1 of 300 000 living newborns [4-8, 11, 12]. It is established that incidence of ALCAPA has no connection with geographical moving of the population, and also there are no data for hereditary nature of developing of this pathology. Moreover, hereditary factors for development of ALCAPA in people having related communications within one family have not been studied. As a rule, ALCAPA isn't associated with any syndromes. The sexual or racial disposition in this anomaly has also not been recorded.

In majority of cases ALCAPA is an isolated heart anomaly, but in rare cases ALCAPA can be combined with PDA, VSD, tetralogy of Fallot and aorta angusta. The following types of an abnormal arising of coronary arteries from a trunk of a pulmonary artery are extremely seldom found:

- arising of the left anterior descending artery or circumflex artery;
- arising of the right coronary artery: it is often found as a casual find on autopsy;
- arising of the left and right coronary arteries, that is not compatible to life.

Approximately 85% of patients within the first 1-2 months of life have clinical symptoms that are characteristic for various degree of a heart failure. In rare cases the clinical picture with signs of an ischemia of myocardium can develop in early childhood [1].

The aim of the research is to describe the clinical case of Anomalous Left Coronary Artery from the Pulmonary Artery (ALCAPA).

Clinical case. Patient K., 6 years old (case history № 2724/144), on 10.12.2015 has admitted into surgical department of congenital heart malformations of the A. N. Syzganov National Scientific Center of Surgery with complaints of pains in heart, weakness, slackness, palpitation at physical activity and frequent headaches.

Anamnesismorbi: According to her mother, the child is ill from August 2013, when she began to complain of pains in heart and headaches. She has been examined by cardiac surgeon, prof. T. Jung (South Korea) and cardiologist J. Song (South Korea). They made EchoCG and recommended a cardiac catheterization with selective polipositional coronarography. She received a conservative therapy in the National Center of Pediatrics and Pediatric surgery (Almaty city), the last hospitalization was in September of 2015.

Anamnesis vitae: The child from the 6th pregnancy, 4th childbirth (the 4th and 5th pregnancies have ended with an abortion). She grew and developed according to age. She is under dispensary supervision of phthisiatrician. There is no hereditary predisposition. There are no allergic reactions to foods and medicines. According to mother, she had no contact with patients with tuberculosis and infectious hepatitis.

Status praesens: General condition is severe due to congenital heart malformation. Consciousness is clear. Constitution is normostenic. Weight – 16kg. Height – 117sm. Body temperature is normal. Lymphatic nodes are not enlarged. Breathing through nose is free. Chest is not deformed. In percussion of lungs the clear pulmonary sound is determined. In auscultation of lungs the vesicular breathing and rales are heard. The breathing rate is 24 motions per minute. In auscultation heart sounds are moderately muffled, regular rhythm, the systolic murmur of non expressed intensity is heard at the apex. The abdomen is of usual form; in palpation it is soft, painful. The liver is palpated at the edge of a costal arch. Urination is free, painless. Stools are of usual color and form.

The results of the carried out clinical, laboratory and instrumental methods of investigation: CBC (10.12.2015): HGB-132g/l, RBC- $4,73 \times 10^{12}/l$, WBC- $9,5 \times 10^9/l$, stick formed NEUT-3%, segment formed NEUT-49%, EO-1%, BA-1%, MON-4%, LYM-42%, ESR-7mm/hour.

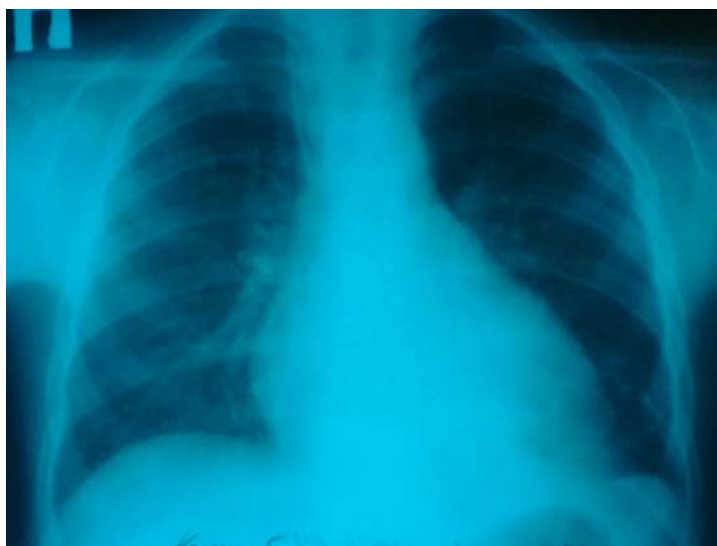CUC (11.12.2015): amount-70,0ml, COLOR-straw yellow, transparency is full, reaction is acidic, SG-1,030, epithel-cells-4-6 in visual field, LEU-1-2in visual field, BLD-0-1 in visual field.

Biochemical blood analysis (10.12.2015): BELOK-66,2gr/l, UREA-2,7mmol/l, CREA-0,04mmol/l, GLU-3,9mmol/l, Ca-2,4mmol/l, K-4,4mmol/l, Na-137mmol/l, ALT-81,6U/L, AST-65,7U/L, BIL-T-10,2mcmol/l, D-BIL-2,1mcmol/l, AMYL-39U/L.

Coagulogram (10.12.2015): APTT-44sec, PTI-74%, INR-1,35, fibrinogen-1,3 g/l, thrombin time-20 sec.

Blood group: O (I) first, Rh (+) positive.

X-ray of the chest (11.12.2015): pulmonary picture is not changed. The roots of lungs are structural. Sinuses are free. The left heart contours are disposed to the left due to enlargement of left ventricle, the waist is kept. Aorta is usual. Cardiothoracic index is 52% (picture 1).



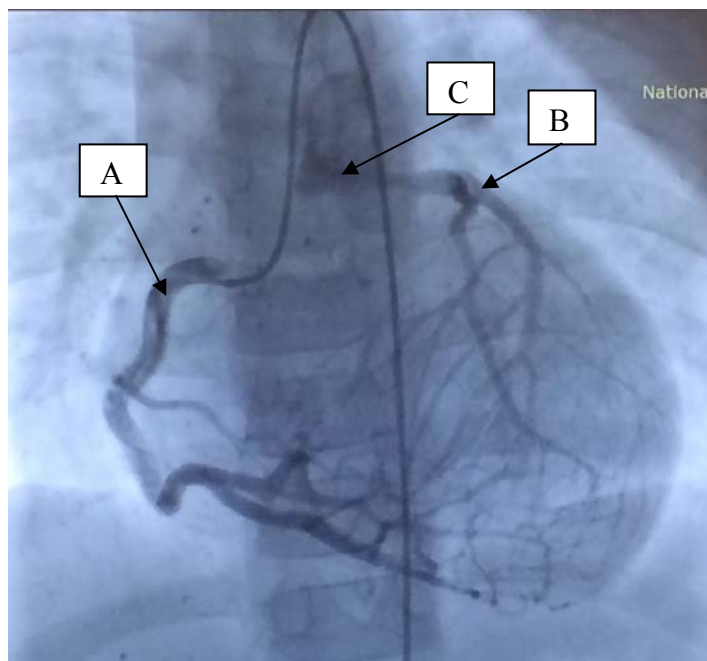
Picture1 – X-ray of the chest of the patient K., 6 years old: enlargement of the left ventricle, cardiothoracic index is 52 %

ECG (11.12.2015): sinus rhythm, heart rate – 91 beats per minute, deviation of the electric axis to the left, the signs left ventricle hypertrophy.

EcoCG (11.12.2015): Aortic valve: tricuspid, leaflets are thin, motile, regurgitation of the 1 degree. Mitral valve: ring diameter-2,2sm, regurgitation of the 1 degree, leaflets are dense; the motility of the posterior leaflet is moderately limited. The pulmonary artery valve: trunk diameter-1,6 cm, leaflets are thin, motile, above the valve of the pulmonary artery there is a turbulent blood stream is 0,2 cm in diameter. Tricuspid valve is without pathology. Left ventricle: EDD-4,5 cm, ESD-3,2 cm, EDV-94 ml, ESV-42 ml, SV-52 ml, EF-55%. Thickness of posterior wall of left ventricle -0,6 cm, thickness of ventricular septum-0,6 cm. The right ventricle: EDD-1,9 cm. Systolic pressure of the right ventricle -22 mm per mercury. Contractility of the left ventricle myocardium is decreased. Left ventricle is enlarged in size. The right chambers are not changed.

Conclusion: Dilatation of the left ventricle. Decrease of the contractility of the left ventricle myocardium. Anomaly of coronary artery development. ALCAPA. Mitral valve insufficiency with regurgitation of the 1-2 degree.

On 10th of the December, 2015 there was performed a selective polipositional coronarography from the right coronary artery: right dominant type of coronary blood supply. There is a hyperplasia of the right coronary artery that has a wavy form throughout. In late arterial phase the left coronary artery is contrasted through intersystem collaterals. In venous phase there is determined a dumping of contrasted blood from trunk of the left coronary artery into trunk of the pulmonary artery (picture 2). Conclusion: ALCAPA.

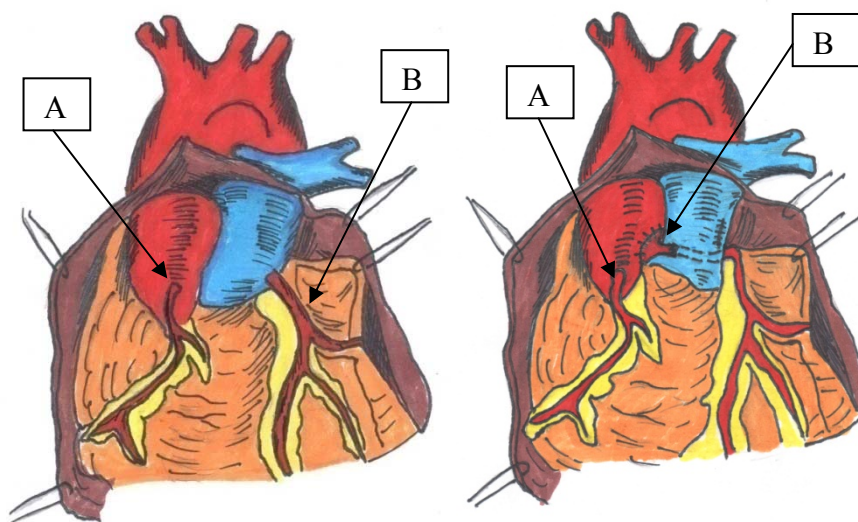


Picture 2 – Selective polipositional coronarography from the right coronary artery.
A – right coronary artery; B – left coronary artery; C – contrast in a trunk of pulmonary artery.

Taking into account the above mentioned data of clinical and instrumental methods of investigation on 11th of the December, 2015 we performed an operation that consisted of transferring of a mouth of the left coronary artery into aorta bypass with pharmacy cold cardioplegia by «Custodiol» and moderate hypothermia (picture 3).

Protocol of operation (picture 3). After quadruple processing of the operational field with solution of povidone the median sternotomy was performed. Autopericardial patch was found. The heart is enlarged due to left chambers. Hemostasis. Aorta was canulated. The separate canulation of the venae cava was performed. Aorta was clamped. Pharmacy cold cardioplegia with «Custodiol» was carried out into root of aorta and trunk of the pulmonary artery. Pulmonary artery was opened. During revision in the region of the posterior sinus the mouth of the left coronary artery was detected. The mouth of the left coronary artery was found on area, the trunk of the left coronary artery was allocated till bifurcation, and in pulling

up to the aorta there was a significant tension. In this connection, the trunk of the left coronary artery is extended by a plastics – ligation of edges of the area throughout 1,0 cm. Further, transverse aortotomy was performed. In a region of the left coronary artery we made a punching of a wall of an aorta with diameter up to 4 mm. The left coronary artery was implanted into aorta (prolen 8/0). Aorta was sutured with two-row seam. There was performed a plastics of the posterior sinus of the pulmonary artery with autopericardial patch (prolen 5/0). Pulmonary artery was sutured. Prophylaxis of the air embolism. The aorta was released. The heart activity was restored with one discharge of defibrillator. Myocardial electrodes were filed. After stabilization of hemodynamics bypass was stopped. Hemostasis. The chest closed with remaining of draining tubes in pericardial cavity and behind a sternum. Layer-by-layer sutures to a wound. The wound was covered by aseptic bandage. Draining tubes were connected to pleural system «Biometrix».



Picture 3 – Schematic image of heart and coronary arteries before and after operation.
A – right coronary artery; B – left coronary artery

The early and hospital postoperational periods proceeded smoothly. The wound healed by primary tension, control CBC and biochemical blood analysis are normal. The patient was discharged under ambulatory supervision of pediatric cardiologist.

Discussion. ALCAPA being a rare type of congenital heart malformation can be one of the most widespread reasons of myocardial ischemia in patients of children's age and often represents a diagnostic problem.

Early diagnostics by help of EcoCG and improvement of the surgical methods of treatment of ALCAPA have considerably improved a prognosis of the disease. In absence of treatment lethality during the first year of child's life is very high owing to secondary ischemia of myocardium or myocardial infarction, but also mitral valve insufficiency leading to a development of the chronic heart failure. Sudden death in patients with ALCAPA is associated with an insufficiency of collateral blood circulation and development of fatal ventricular arrhythmias.

In a number of works on functional diagnostics there were noticed 9 indirect informational Doppler-EcoCG signs the presence of which can testify to ALCAPA: expressed dilation of the left ventricle; decrease of pump function of the left ventricle; formation of left ventricular aneurysm; consolidation of left ventricular endocardium; dilation of the fibrous ring of mitral valve; mitral valve insufficiency; dilation of a mouth and proximal part of right coronary artery; absence of visualization of a mouth of the left coronary artery in a place of its usual arising; systole-diastolic stream in pulmonary artery according to data of EcoCG [1].

Nowadays selective polipositional coronarography and left ventriculography are the «gold standard» in a diagnostics of the congenital coronary anomalies, including ALCAPA. The given method is more informative concerning topical diagnostics of the anomaly. The necessity in reconstruction or prosthetic

replacement of the mitral valve in ALCAPA depends on a development of hemodynamic complications caused by mitral valve insufficiency [12]. There was described a case of aneurysm of the left coronary artery in ALCAPA [4].

In a literature there were given the following variants of surgical interventions in ALCAPA [1, 6, 8, 12]:

1) ligation of the mouth of an anomalous coronary artery for liquidation of the steal-syndrome. The operation is performed only in case of well developed collaterals. All loads lay down on a normal right coronary artery;

2) CAG of an abnormally arising left coronary artery;

3) a translocation of a mouth of the left coronary artery into aorta. The aim of this operation is a transferring of a mouth of the left coronary artery on area into aorta;

4) acreation of an intrapulmonary tunnel (Takeuchi procedure);

5) amammarocoronary shunting of an abnormal arising of the left coronary artery.

Conclusion. Thus, ALCAPA is a rare type of the congenital heart malformation that is found in a clinical practice. The peculiarities of hemodynamic disorders, clinical course and diagnostics of ALCAPA determine the necessity of the earlier diagnostics and surgical treatment.

REFERENCES

- [1] Bokeriya L.A., Arnautova I.V. Anomalnoe othojdenie leveo koronarnoi arterii ot legochnoi arterii (sindrom Blanda-Uaita-Garlanda: gemodinamika, klinicheskoe techenie i diagnostika. Detskie bolezni serdca i sosudov. 2012. N 4. P. 4-12 (in Russ.).
- [2] Abbott M.E. Congenital Cardiac disease. Modern Medicine. Philadelphia, 1908 (in Eng.).
- [3] Bland E.F., White P.D., Garland J. Congenital anomalies of the coronary arteries: report of an unusual case associated with cardiac hypertrophy. 1933. 8: 787-801 (in Eng.).
- [4] Bravo-Valenzuela NJ, Silva GR. Aneurysm of the Left Coronary Artery in Postoperative Bland-White-Garland Syndrome. Case Rep Cardiol. 2015; 2015: 568014. doi: 10.1155/2015/568014. Epub 2015 Dec 6 (in Eng.).
- [5] Brooks S.J. Two cases of abnormal coronary artery of the heart arising from the pulmonary artery: with some remarks upon the effect of this anomaly in producing cirroid dilation of the vessels // J. Anat. Physiol. 1886. Vol. 20. P. 26-32 (in Eng.).
- [6] Erdinc M, Hosgor K, Karahan O. Repair of anomalous origin of the left coronary artery arising from right pulmonary artery with rolled-conduit-extended reimplantation in an adult // J. Card Surg. 2011 Nov. 26(6): 604-607 (in Eng.).
- [7] Juan C.C., Hwang B., Lee P.C., Meng C.C. Diagnostic application of multidetector-row computed tomographic coronary angiography to assess coronary abnormalities in pediatric patients: comparison with invasive coronary angiography // *Pediatr Neonatol.* 2011 Aug. 52(4): 208-213 (in Eng.).
- [8] Kazmierczak P.A., Ostrowska K., Dryzek P., et al. Repair of anomalous origin of the left coronary artery from the pulmonary artery in infants. *Interact CardiovascThorac Surg.* 2013 Jun. 16(6):797-801 (in Eng.).
- [9] Sagatov I.Ye. Dynamics of u-NGAL in cardiac surgical patients in early postoperational period. The Journal of Cardiovascular Surgery 2016. April; 57(Suppl. 2 to N2): 105 (in Eng.).
- [10] Sagatov I.Ye. Modeling of the operational risk in patients with congenital heart diseases. Cardiology 2015; 131 (Suppl 1): 29-30 (in Eng.).
- [11] Secinaro A., Ntsinjana H., Tann O., Schuler P.K., Muthurangu V., Hughes M., et al. Cardiovascular magnetic resonance findings in repaired anomalous left coronary artery to pulmonary artery connection (ALCAPA) // *J CardiovascMagnReson.* 2011 May 16. 13:27 (in Eng.).
- [12] Su L.S., Burkhart H.M., O'Leary P.W., Dearani J.A. Mitral valve arcade with concomitant anomalous left coronary artery from the pulmonary artery. *AnnThoracSurg.* 2011 Dec. 92(6): e121-123 (in Eng.).

**И. Е. Сағатов^{1,2}, Jun Tae-Gook³, Song Jinyoung³,
Қ. О. Оңғарбаев¹, У. Е. Имаммырзаев¹, А. Б. Аймамбетова¹**

¹А. Н. Сызганов атындағы Ұлттық ғылыми хирургия орталығы, Алматы, Қазақстан,

²Қазақ медициналық үздіксіз білім беру университеті, Алматы, Қазақстан,

³Samsung Medical Center School of Medicine, Sungyunkwan University, Seoul, South Korea

ALCAPA (BLAND-WHITE-GARLAND СИНДРОМЫ) БАР 6 ЖАСАР ҚЫЗДЫ ОТАЛАУ ЕМІНІҢ КЛИНИКАЛЫҚ СИПАТТАМАСЫ

Аннотация. Мақалада ALCAPA (Bland-White-Garland синдромы) бар 6 жасар қызды оталау емінің клиникалық сипаттамасы баяндалған.

Түйін сөздер: ALCAPA, балалар.

**И. Е. Сагатов^{1,2}, Jun Tae-Gook³, Song Jinyoung³,
К. О. Онгарбаев¹, У. Е. Имаммырзаев¹, А. Б. Аймамбетова¹**

¹Национальный научный центр хирургии им. А. Н. Сызганова, Алматы, Казахстан,

²Казахский медицинский университет непрерывного образования, Алматы, Казахста,

³Samsung Medical Center School of Medicine, Sungyunkwan University, Seoul, South Korea

**КЛИНИЧЕСКИЙ СЛУЧАЙ ХИРУРГИЧЕСКОГО ЛЕЧЕНИЯ 6-ЛЕТНЕЙ ДЕВОЧКИ
С ALCAPA (СИНДРОМ BLAND-WHITE-GARLAND)**

Аннотация. В статье представлен клинический случай успешного хирургического лечения пациентки 6-и лет с ALCAPA (синдром Bland-White-Garland).

Ключевые слова: ALCAPA, дети.

Сведения об авторах:

Сагатов Инкар Ергалиевич – доцент кафедры сердечно-сосудистой и эндоваскулярной хирургии КазМУНО, главный научный сотрудник ННЦХ им. А. Н. Сызганова, доктор медицинских наук, e-mail: inkar_sagatov@rambler.ru

Tae-Gook Jun – профессор, руководитель отдела хирургического лечения врожденных пороков сердца Samsung Medical Center School of Medicine, Sungyunkwan University, M.D., Ph.D.

Publication Ethics and Publication Malpractice in the journals of the National Academy of Sciences of the Republic of Kazakhstan

For information on Ethics in publishing and Ethical guidelines for journal publication see <http://www.elsevier.com/publishingethics> and <http://www.elsevier.com/journal-authors/ethics>.

Submission of an article to the National Academy of Sciences of the Republic of Kazakhstan implies that the described work has not been published previously (except in the form of an abstract or as part of a published lecture or academic thesis or as an electronic preprint, see <http://www.elsevier.com/postingpolicy>), that it is not under consideration for publication elsewhere, that its publication is approved by all authors and tacitly or explicitly by the responsible authorities where the work was carried out, and that, if accepted, it will not be published elsewhere in the same form, in English or in any other language, including electronically without the written consent of the copyright-holder. In particular, translations into English of papers already published in another language are not accepted.

No other forms of scientific misconduct are allowed, such as plagiarism, falsification, fraudulent data, incorrect interpretation of other works, incorrect citations, etc. The National Academy of Sciences of the Republic of Kazakhstan follows the Code of Conduct of the Committee on Publication Ethics (COPE), and follows the COPE Flowcharts for Resolving Cases of Suspected Misconduct (http://publicationethics.org/files/u2/New_Code.pdf). To verify originality, your article may be checked by the Cross Check originality detection service <http://www.elsevier.com/editors/plagdetect>.

The authors are obliged to participate in peer review process and be ready to provide corrections, clarifications, retractions and apologies when needed. All authors of a paper should have significantly contributed to the research.

The reviewers should provide objective judgments and should point out relevant published works which are not yet cited. Reviewed articles should be treated confidentially. The reviewers will be chosen in such a way that there is no conflict of interests with respect to the research, the authors and/or the research funders.

The editors have complete responsibility and authority to reject or accept a paper, and they will only accept a paper when reasonably certain. They will preserve anonymity of reviewers and promote publication of corrections, clarifications, retractions and apologies when needed. The acceptance of a paper automatically implies the copyright transfer to the National Academy of Sciences of the Republic of Kazakhstan.

The Editorial Board of the National Academy of Sciences of the Republic of Kazakhstan will monitor and safeguard publishing ethics.

Правила оформления статьи для публикации в журнале смотреть на сайте:

www.nauka-nanrk.kz

ISSN 2518-1629 (Online), ISSN 2224-5308 (Print)

<http://www.biological-medical.kz/index.php/ru/>

Редактор *М. С. Ахметова*
Верстка на компьютере *Д. Н. Калкабековой*

Подписано в печать 14.10.2016.
Формат 60x881/8. Бумага офсетная. Печать – ризограф.
11,75 п.л. Тираж 300. Заказ 5.